

Available online at www.sciencedirect.com

ScienceDirect

journal homepage: www.elsevier.com/locate/radcr

Case Report

pTEVAR of an aorto-esophageal fistula in esophageal cancer: Case report and review of the literature ☆☆☆

Andreas D. Owczarek, MD^{a,*}, Simon Viniol, MD^a, Alexander M. König, MD^a, Jannis Görlach, MD^a, Ulrike W. Denzer^b, Petros Stathopoulos, MD^b, Andreas H. Mahnken^a

^a Department of Diagnostic and Interventional Radiology, University Hospital Marburg, Philipps University of Marburg, Baldingerstrasse, D-35043, Marburg, Germany

^b Clinic for Gastroenterology, Endocrinology, Metabolism and Clinical Infectiology, University Hospital Marburg, Philipps University of Marburg, Marburg, Germany

ARTICLE INFO

Article history:

Received 9 March 2023

Revised 19 April 2023

Accepted 22 April 2023

Available online 18 May 2023

Keywords:

Gastrointestinal bleeding

Esophageal cancer

Aorto-esophageal fistula

Percutaneous thoracic endovascular repair

Endovascular treatment

ABSTRACT

An aorto-esophageal fistula (AEF) is a rare and life-threatening situation, associated with aneurysms, foreign bodies, infiltrating tumors, and radiotherapy. The ideal management is unclear. Open surgery of AEF has a high mortality and morbidity. Thoracic endovascular aortic repair (TEVAR) of an AEF is an effective and safe emergency treatment for these patients. We describe a case of AEF due to esophageal cancer successfully treated the first time by total percutaneous TEVAR (pTEVAR). A 70-year-old male patient presented with massive hematemesis at the emergency department. The patient had a known history of esophageal cancer previously treated by radiochemotherapy which was completed 3 days before. Emergency upper gastrointestinal endoscopy failed to stop the bleeding. Subsequent contrast-enhanced computed tomography revealed an aorto-esophageal fistula and emergency pTEVAR was performed. The bleeding stopped directly after stent graft placement and the patient was discharged after 10 days later. He died 3 months after pTEVAR from cancer progression. pTEVAR is an effective and safe treatment option for AEF. It can be applied as a first-line treatment and offers the potential to improve survival in the emergency setting.

© 2023 The Authors. Published by Elsevier Inc. on behalf of University of Washington.

This is an open access article under the CC BY-NC-ND license

(<http://creativecommons.org/licenses/by-nc-nd/4.0/>)

Abbreviations: AEF, aorto-esophageal fistula; BE, Belgium; CRT, chemoradiotherapy; CT, chemotherapy; CTA, computed tomography angiography; F, French; NBCA, N-butyl cyanoacrylate; pTEVAR, percutaneous thoracic endovascular repair; RT, radiotherapy; TEVAR, thoracic endovascular repair.

☆ Acknowledgments: Open Access funding provided by the Open Access Publishing Fund of Philipps-Universität Marburg with support of the Deutsche Forschungsgemeinschaft (DFG, German Research Foundation).

☆☆ Competing Interests: The authors declare that they have no known competing financial interests or personal relationships that could have appeared to influence the work reported in this paper.

* Corresponding author.

E-mail address: andreasowczarek@gmx.de (A.D. Owczarek).

<https://doi.org/10.1016/j.radcr.2023.04.037>

1930-0433/© 2023 The Authors. Published by Elsevier Inc. on behalf of University of Washington. This is an open access article under the CC BY-NC-ND license (<http://creativecommons.org/licenses/by-nc-nd/4.0/>)

Introduction

Aorto-esophageal fistula (AEF) is a rare entity with an annual incidence of 0.007 per million. Its key symptom is massive upper gastrointestinal tract bleeding via the communication between the aorta and the esophagus [1,5]. Untreated it is generally fatal. Advanced esophageal cancer with aortic invasion is the third common cause of AEF, after thoracic aortic aneurysm and foreign body ingestion [1–3]. Regardless of cause, the ideal management of the fistula remains unclear and up to now there are no generally accepted treatment guidelines [4,5]. Current literature has focused on the role of endovascular techniques and open thoracic surgery for dealing with AEF. pTEVAR is a rapid and safe procedure that is increasingly used in the endovascular management of aortic aneurysms. It also holds the potential to be safe and effective in AEF. However, there is no data on its use in this particular condition.

Case report

A 70-year-old male presented to the emergency department with massive hematemesis. The patient had a known history of treated bladder carcinoma 2 years ago and most recently advanced esophageal squamous-cell carcinoma (T4N+ cMX). The latter was treated by radiochemotherapy with 64 Gy external beam radiation and a combination of paclitaxel and carboplatin. Therapy was completed 3 days before presentation at the emergency department after 2 months of treatment. After admission, the patient immediately received fluid resuscitation and was instantaneously transferred to the endoscopy unit. Emergency upper gastro-intestinal endoscopy showed an ulcerated pulsating bleeding esophageal cancer (Fig. 1).

The bleeding could not be stopped and computed tomography angiography (CTA) was performed to identify a suspected AEF. CTA demonstrated communication between the esophagus and the descending aorta as well as a pseudoaneurysm of the descending aorta (Fig. 2).

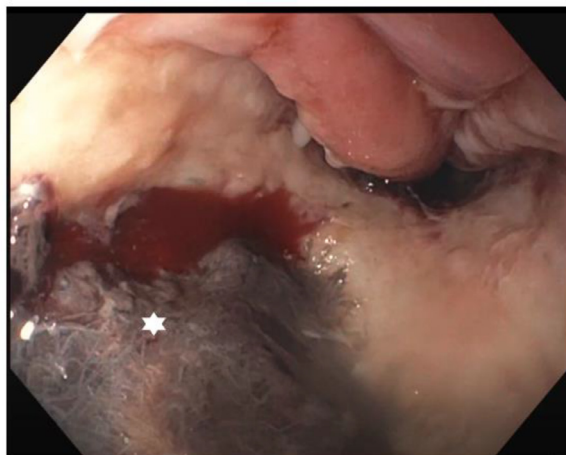

Fig. 1 – Endoscopy showed a pulsating and bleeding ulcerated esophageal cancer (asterisk).

Due to the unstable hemodynamics the patient was immediately transferred to the interventional radiology department and pTEVAR was performed. Access was created by bilateral percutaneous puncture of the femoral artery. An 0.035-inch guidewire was advanced from each side into the aorta and the left puncture site was dilated with a 5F sheath and the right puncture site with a 7F sheath. On the right side a suture-based closure device was advanced over the guidewire (Perclose ProGlide, Abbott, Santa Clara, CA) rotated medially and deployed. The sutures were left extracorporally and fixed with a small clamp. Guidewire access was maintained, and a second device was introduced, rotated laterally and deployed in an identical fashion. After removing the device a 22F sheath was inserted over the wire. A pigtail catheter from the left side was used for angiography that showed the fistula as an irregularity of the descending aorta (Fig. 3A). Thereafter, a 28-mm diameter and 157 mm long stent graft (Valiant, Medtronic, Minneapolis, MN) was placed in order to cover the entire lesion (Fig. 3B). The bleeding instantaneously stopped and vital signs stabilized. Left femoral access was closed on the left with 6F closure device (Angioseal, Terumo, Leuven, BE). Right femoral access was closed by fastening the knots of the previously deployed suture based vascular closure systems while an 0.035-inch wire was left in place. As this did not achieve sufficient hemostasis an additional 8F closure device (AngioSeal, Terumo, Leuven, BE) was placed over the remaining guidewire supported by manual compression. The patient left the interventional radiology department in stable condition. During follow-up there were no signs of complications at the vascular access site. He was treated with 2 g ceftriaxone and 500 mg metronidazole and was discharged after 10 days in hospital in stable condition. The patient died 3 months after pTEVAR from cancer progression.

Discussion

AEF is a rare condition that causes upper gastrointestinal bleeding. In the literature there are just few cases of AEF due to esophageal cancer treated by TEVAR [4]. Historically therapy of this condition consisted of surgical repair of the aorta and the esophagus. However, the mortality of an open surgical approach ranges from 45.4% to 55% [6]. TEVAR in comparison is a rapid, less invasive and more cost-effective intervention which has a high technical success rate (87.3%) and a more favorable 30-day mortality rate (19.7%) in patients with AEF [4,6–8]. TEVAR can extend the survival time by an average of 4 months in the context of AEF due to esophageal cancer [4]. In case of ruptured fistula, open thoracic surgery may therefore be offered to patients with AEF who are in relatively good physical condition. TEVAR should be considered the treatment of choice for patients with an AEF in an emergency setting or who are in a poor condition as it causes less tissue damage, requires no aortic clipping, and is associated with less cerebral ischemic damage while providing excellent hemostasis [4].

With a total percutaneous approach as reported in this case the tissue damage can be reduced further and procedure time can potentially be shortened, which is an invaluable advantage in an emergency setting with large volume blood loss.

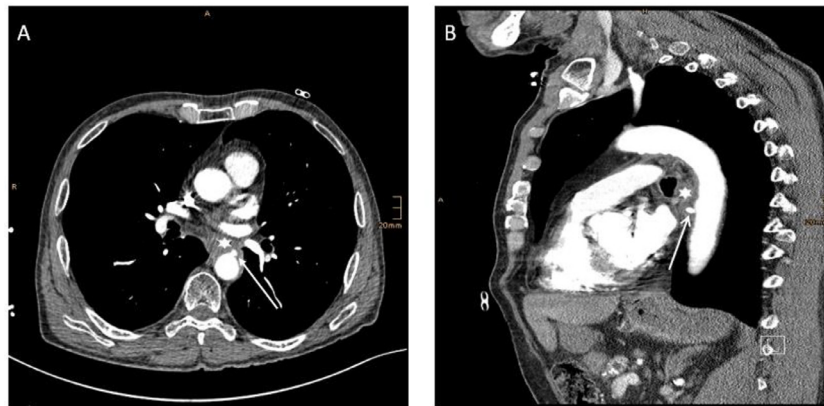


Fig. 2 – CTA demonstrates the connection between the descending aorta (arrow) and esophagus (asterisk) in form of a pseudoaneurysm in axial (A) and sagittal view (B).

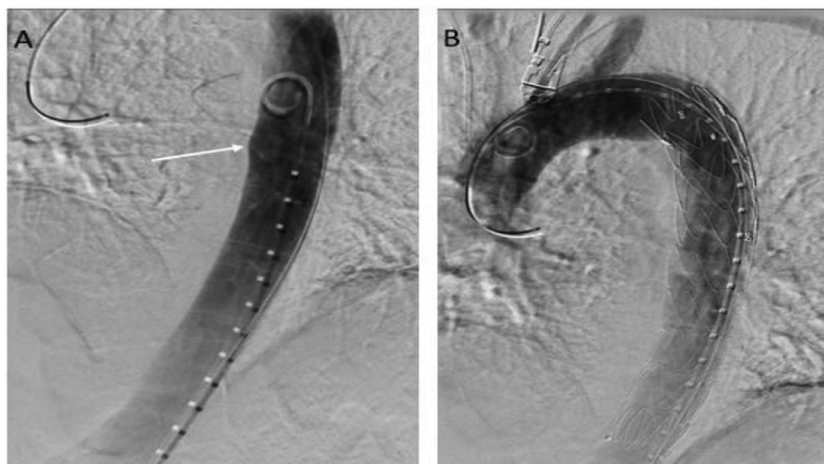


Fig. 3 – pTEVAR of AEF. (A) Aortic angiography shows an irregularity of the aortic wall (arrow). (B) The fistula was covered with an aortic stent graft using a pTEVAR approach.

Moreover, it goes along with less patient discomfort and lower procedural cost [9]. However, while it is increasingly used in endovascular aortic aneurysm repair there are no reports on a total percutaneous approach for endovascular repair in AEF.

Vascular complications are a known problem in TEVAR, but reported to be less when commonly used closure devices are applied [10,11]. As the suture-based closure device achieved an insufficient initial result in this patient, an additional anchor-collagen-based closure device supported by manual compression was successfully added as bail-out measure to achieve hemostasis. As failure rate is described to be about 2%-8% and leads to a higher risk of vascular complication, it is crucial to know about bail-out strategies [12]. Combination of different types of closure devices with or without additional manual compression could be a promising option if a suture-based closure device fails to achieve hemostasis.

In literature, there are reports about 20 patients treated with TEVAR in context of AEF due to esophageal cancer. Of 21 patients, including our case, 17 were men and 4 women.

The average age was 64.4 years. 4 patients were alive during follow-up, 2 died during intervention and the average survival time of the rest was 3.9 months [15]. It seems that exposure to radiotherapy with doses higher than 35 Gy and implantation of esophageal stents in the medical history are risk factors for developing AEF [6,13]. In 9 patients, TEVAR was performed to cover the fistula without any further intervention [4,7,15,17–20]. The combination of TEVAR followed by surgery could be an alternative. Of 2 patients one was still alive in follow-up [5,8]. However, patients are often in too bad condition to undergo surgery. Esophageal stenting in addition to TEVAR was performed in 7 cases. Until now it remains unclear whether stenting before or after TEVAR is more efficient [2,6,13,16].

Novel hemostatic approaches to improve preoperative hemodynamics before TEVAR are options to be investigated in future. Embolization with a mixture of lipiodol and N-butyl cyanoacrylate (NBCA) to achieve preoperative hemostasis is an promising option. Chen et al. [15] reported about 2 patients which were successfully stabilized after embolization with

NBCA before stent-graft implantation. In contrast to the use of NBCA embolization alone as patients died on hemorrhagic shock within 3 days [15]. However, all of these additional measures require additional time when compared to pTEVAR. Therefore, the sole use of pTEVAR is an appealing strategy to manage AEF in an emergency situation.

One relevant problem still to be solved is to prevent contamination through the fistula. Graft infection with subsequent sepsis is one of the major causes of death after TEVAR [7]. The literature indicates potential benefits from the long-term use of antibiotics and the implantation of an additional esophageal stent to prevent the contact of the endograft with the septic environment of the esophagus to reduce the risk of graft infection and sepsis. The use of antimicrobial coatings on the surface of stent grafts is another option to and discussed for the future [2,4,6]. Considering these limitations, TEVAR for AEF may need subsequent open repair [6,13,14].

Conclusion

Esophageal cancer patients with severe hematemesis should undergo emergency contrast-enhanced computed tomography as a first-line measure. Rapid and correct diagnosis is essential and possibly lifesaving when developing the most effective treatment strategy in potential AEF patients. pTEVAR is effective for AEF caused by esophageal cancer especially for those who are not fit for open surgery or not suited for curative treatment. It offers several advantages over conventional TEVAR with surgical exposure of femoral artery, including shorter procedure time. Therefore, pTEVAR should be considered a treatment of choice in emergency patients suffering from AEF.

Author contributions

ADO and AHM drafted the manuscript. All authors read and approved the final manuscript.

Ethics approval and consent to participate

Not applicable.

Availability of data and materials

Not applicable.

Patient consent

Written consent was obtained for the publication of the current case.

REFERENCES

- Lin S-H, Lee J-M, Wu I-H. Comparison of clinical outcomes between salvage and elective thoracic endovascular aortic repair in patients with advanced esophageal cancer with aortic invasion: a retrospective cohort study. *Biomedicines* 2021;9(12):1–11. doi:10.3390/biomedicines9121889.
- Ghosh SK, Rahman FZ, Bown S, Harris P, Fong K, Langmead L. Survival following treatment of aorto-esophageal fistula with dual esophageal and aortic intervention. *Case Rep Gastroenterol* 2011;5(1):40–4. doi:10.1159/000323700.
- Lee RY, Flaherty L, Khushalani NI, Kanehira K, Nwogu C, Yendamuri S, et al. Aorto-esophageal fistula: a rare fatal case caused by esophageal malignancy. *J Gastrointest Oncol* 2010;1(1):64–5. doi:10.3978/j.issn.2078-6891.2010.006.
- Zhong X-Q, Li G-X. Successful management of life-threatening aorto-esophageal fistula: a case report and review of the literature. *WJCC* 2022;10(12):3814–21. doi:10.12998/wjcc.v10.i12.3814.
- Ikeda Y, Morita N, Kurihara H, Niimi M, Okinaga K. A primary aorto-esophageal fistula due to esophageal carcinoma successfully treated with endoluminal aortic stent grafting. *J Thorac Cardiovasc Surg* 2006;131(2):486–7. doi:10.1016/j.jtcvs.2005.08.042.
- Sasaki A, Egashira H, Tokoro S, Ichita C, Takizawa S, Tsukiyama T, et al. Thoracic endovascular aortic repair of esophageal cancer-associated aorto-esophageal fistula: a case report and literature review. *Case Rep Oncol Med* 2018;2018:9851397. doi:10.1155/2018/9851397.
- Ishikawa N, Maruta K, Oi M, Iizuka H, Kawaura H, Omoto T, et al. Thoracic endovascular repair for aorto-esophageal fistula in patients with esophageal carcinoma: report of 3 cases. *Vasc Endovasc Surg* 2013;47(1):65–9. doi:10.1177/1538574412467858.
- Iwabu J, Namikawa T, Yokota K, Kitagawa H, Kihara K, Hirose N, et al. Successful management of aorto-esophageal fistula caused by esophageal cancer using thoracic endovascular aortic repair. *Clin J Gastroenterol* 2020;13(5):678–82. doi:10.1007/s12328-020-01132-5.
- Huff CM, Silver MJ, Ansel GM. Percutaneous endovascular aortic aneurysm repair for abdominal aortic aneurysm. *Curr Cardiol Rep* 2018;20(9):79. doi:10.1007/s11886-018-1023-6.
- Thurston JS, Camara A, Alcasid N, White SB, Patel PJ, et al. Outcomes and cost comparison of percutaneous endovascular aortic repair versus endovascular aortic repair with open femoral exposure. *J Surg Res* 2019;240:124–9. doi:10.1016/j.jss.2019.02.011.
- Rebelo A, Voss P, Ronellenfitsch U, Sekulla C, Ukkat J. Comparison of percutaneous and cutdown access-related minor complications after endovascular aortic repair. *Exp Ther Med* 2022;24(4):626. doi:10.3892/etm.2022.11563.
- Chen I-M, Lee T-H, Chen P-L, Shih C-C, Chang H-H. Factors in ProGlide® vascular closure failure in sheath arteriotomies greater than 16 French. *Eur J Vasc Endovasc Surg* 2019;58(4):615–22. doi:10.1016/j.ejvs.2019.03.037.
- Guerrero I, Cuenca JA, Cardenas YR, Nates JL. Hemorrhagic shock secondary to aorto-esophageal fistula as a complication of esophageal cancer. *Cureus* 2020;12(2):e7146. doi:10.7759/cureus.7146.
- Queiroz de Sousa G, Fernandes e Fernandes R, Mendes Pedro L, Garrido P, Silvestre L, Costa P, et al. Aorto-esophageal fistula in a patient with carcinoma of the esophagus: case report. *Angiol Cirur Vasc* 2016;12(3):214–17. doi:10.1016/j.ancv.2016.03.003.
- Chen C, Kim JW, Shin JH, Kwon Y, Kim J, Lee JJ. Management of life-threatening aorto-esophageal fistula: experiences

- learned from eight patients. *Acta Radiol* (Stockholm, Sweden: 1987) 2021;62(4):447–452. doi:[10.1177/0284185120933228](https://doi.org/10.1177/0284185120933228).
- [16] Wong PC, Chan YC, Law Y, Keung C, Stephen W. Emergency aortic stent-graft treatment for malignant aorto-esophageal fistula. *Asian Cardiovasc Thorac Ann* 2017;25(9):649–52. doi:[10.1177/0218492317741788](https://doi.org/10.1177/0218492317741788).
- [17] Dorweiler B, Weigang E, Duenschede F, Pitton MB, Dueber C, Vahl C-F. Strategies for endovascular aortic repair in aortobronchial and aorto-esophageal fistulas. *Thorac Cardiovasc Surg* 2013;61(7):575–80. doi:[10.1055/s-0033-1347294](https://doi.org/10.1055/s-0033-1347294).
- [18] Feezor RJ, Hess PJ, Lee WA. Endovascular treatment of a malignant aorto-esophageal fistula. *J Vasc Surg* 2009;49(3):778. doi:[10.1016/j.jvs.2008.05.066](https://doi.org/10.1016/j.jvs.2008.05.066).
- [19] Kato N, Tadanori H, Tanaka K, Yasuda F, Iwata M, Kawarada M, et al. Aorto-esophageal fistula-relief of massive hematemesis with an endovascular stent-graft. *Eur J Radiol* 2000;34(1):63–6. doi:[10.1016/s0720-048x\(99\)00107-2](https://doi.org/10.1016/s0720-048x(99)00107-2).
- [20] Nagata T, Wang Y, Asanuma M. Emergency thoracic aortic stent grafting for aorto-esophageal fistula in advanced esophageal cancer. *J Card Surg* 2017;32(10):650–1. doi:[10.1111/jocs.13218](https://doi.org/10.1111/jocs.13218).