Aus der Klinik für Augenheilkunde
Direktor: Prof. Dr. P. Kroll
des Fachbereichs Medizin der Philipps-Universität Marburg

in Zusammenarbeit mit dem Universitätsklinikum Gieβen und Marburg GmbH,
Standort Marburg

Treatment for Central Retinal Vein Occlusion: Radial Optic Neurotomy vs. Conservative Therapy. One Year Follow-up

Inaugural-Dissertation zur Erlangung des Doktorgrades der gesamten Humanmedizin
dem Fachbereich Medizin der Philipps-Universität Marburg
vorgelegt von

Josep Callizo aus Barcelona
Marburg, 2007

Angenommen vom Fachbereich Medizin der Philipps-Universität Marburg am: 05.07.2007

Gedruckt mit Genehmigung des Fachbereichs.

Dekan: Prof. Dr. B. Maisch
Referent: PD Dr. C. Meyer
1. Korreferent: Prof. Dr. Hamer

Zusammenfassung

Das Ziel der vorliegender Arbeit umfasst den Vergleich der anatomischen und funktionellen Ergebnisse nach konservativer und chirurgischer Therapie bei Patienten mit Zentralvenenverschluss (ZVV) in einer prospektiven nicht randomizierten Studie. Zusätzlich untersuchten wir die Visusentwicklung nach radiärer Optikusneurotomie (RON) bei ischämischem versus nicht-ischämischem ZVV und den Einfluss der Entwicklung chorioretinaler Anastomosen (CRA) auf den Visuserfolg und auf die retinale Perfusion.

Es wurden 63 Augen von 63 konsekutiven Patienten mit ZVV in die Studie eingeschlossen. Bei 28 Augen erfolgte eine pars-plana-Vitrektomie mit radiärer Optikusneurotomie (Gruppe A), während bei 35 Augen eine konservative Therapie durchgeführt wurde (Gruppe B). Das Einschlusskriterium fur die Operation war ein ausgeprägter hämorragischer ZVV mit einem präoperativen Snellen Visus von 0,3 oder schlechter. Vor Therapiebeginn, sowie 12 Monate nach der Behandlung wurden folgende Untersuchungen durchgeführt: Visus, Augeninnendruck, Spaltlampenuntersuchung, Fundusuntersuchung, und Fluoreszenzangiographie. Die Messung der arteriovenösen Perfusionszeit und der retinalen Perfusion erfolgte mittels Fluoreszenzangiographie.

Der präoperative Mittelwert des Visus in Gruppe A lag bei 0,1, in Gruppe B bei 0,23. Nach einem Jahr hatten die Patienten der Neurotomiegruppe eine Visusverbesserung um 2,51 Linien verglichen mit 0,60 in Gruppe B (signifikant nur in der Gruppe A). Die arteriovenöse Perfusionszeit verbesserte sich signifikant ebenfalls nur in der Gruppe A. Die Entwicklung einer CRA war in der Gruppe A 10 fach häufiger als in Gruppe B (57,15 vs. 5,7%). In jener Subgruppe mit Anastomosenausbildung (CRA) nach Operation, zeigte sich ein signifikant größerer Visusanstieg.

Nicht-ischämische und hämorrhagische Augen zeigten eine größere Visus- und Perfusionbesserung nach Chirurgie.

Die Inzidenz von Komplikationen und die Notwendigkeit zusätzlicher Behandlung waren in der Gruppe A deutlich geringer.

In dieser klinisch nichtrandomizierter Studie erweist sich RON als ein sicheres und wirksames Operationsverfahren, um den Verlauf des ZVV bei Patienten mit anfänglich schlechtem Visus, die sonst eine geringe Chance auf signifikante spontane visuelle Erholung hätten, zu verbessern. Unsere Studie zeigte zusätzlich, dass nach RON möglicherweise eine signifikant stärkere Visusverbesserung erzielt wird, verglichen mit einer konservativen Therapie. Die Entwicklung von chorioretinalen Anastomosen scheint eine der zugrundeliegenden Mechanismen für die Verbesserung zu sein.

Abstract

The aim of this study was to evaluate in a prospective nonrandomised way the long-term effectiveness and safety of the surgical technique consisting in pars plana vitrectomy and radial optic neurotomy as therapy for central retinal vein occlusion (CRVO) compared with conservative treatment. In addition, we wanted to compare the effects of surgery in ischemic and non-ischemic CRVO and evaluate the influence of chorioretinal anastomosis (CRA) on retinal perfusion and visual acuity.

Twenty-eight patients (group A) underwent pars plana vitrectomy and radial optic neurotomy (RON) and 35 patients (group B) were conservatively treated and followed as control. In the surgery group were eyes included with VA of 0,3 or worse. Visual acuity, retinal perfusion, time of arteriovenous transit on fluorescein angiography and development of chorioretinal anastomosis were analised at onset and one year after treatment.

The initial mean visual acuity in group A was 0,1 and 0,23 in group B. After 1 year, patients in group A experienced a mean gain of lines of 2,51 compared with 0.63 in group B (significant only in group A). Similarly, time of arteriovenous transit improved significantly only in group A. Development of chorioretinal anastomosis was much higher after RON (57%) than in the conservative group (5,7%). In both groups the development of CRA correlated with a better visual recovery.

Non-ischemic and hemorrhagic CRVO showed a greater functional improvement after RON than ischemic CRVO.

The incidence of complications and the need for an additional treatment were signficantly lower in group A.

In our study, compared with a conservative therapy, RON shows a better improvement of visual acuity and retinal perfusion in patients with CRVO, specially in those eyes with a non-ischemic or hemorrhagic occlusion and initially poor vision who have, otherwise, a low chance of significant spontaneous visual recovery. The development of chorioretinal anastomosis may play an important role in the improvement of retinal perfusion and visual function.

Table of Contents

Table of Contents

1. INTRODUCTION

Retinal venous occlusive disease (including both branch and central vein occlusion) is by far the most common retinal vascular occlusive disorder and, following diabetic retinopathy, the second vascular cause of loss of vision in the eye.

Acute occlusion of the central retinal vein presents as one of the most dramatic pictures in ophthalmology and, despite many years of investigation since it was first described, its pathophysiology and a standard treatment remain unclear. The prognosis of the disease is particularly poor in those eyes developing a retinal ischemia after the thrombosis, and its therapy presents as a challenge for the ophthalmologist.

1.1 Epidemiology

The prevalence of central retinal vein occlusion (CRVO) is 0,2% by population over 40 years old (Klein 2000). If we distinguish, regarding retinal perfusion, between ischemic and nonischemic central retinal vein occlusion the average age of patients presenting with nonischemic CRVO is the early to mid 60s while the average age of patients presenting with ischemic CRVO is around 70 years old. There is a slight male preponderance (Mitchell 1996). 50% to 70% have associated hypertension, cardiovascular disease or diabetes mellitus (Mieler 1982, Appiah 1989). The cumulative probability of developing a second episode of a retinal vein occlusion in the same eye is 0,9% within two years and 2,5% within four years, and in the fellow eye 7,7% and 11,9% respectively (Pollack 1989, Hayreh 1994).

1.2 Etiology

The pathogenesis of CRVO is thought to be a thrombosis in the central retinal vein at the level of the lamina cribosa (Klein 1953).

The precise etiology of CRVO is not entirely clear. There are now some clues as to the conditions associated with this pathology. Many articles have reported on the association between central retinal vein occlusion and some other condition, whether systemic or ocular (Elman 1990, The Eye Disease

Case-Control Study Group 1996). Although some of these associated conditions probably are, in some cases, related to central retinal vein occlusion, there is no way to determine in most cases whether the association is only coincidental on the basis of single case reports. The only one prospective large study of risk factors for CRVO with an appropriate age- and sex-matched control group, published in 1996 by the Eye Disease Case-Control Study Group, found an increased risk in patients with systemic hypertension (odds ratio 2,1), diabetes mellitus (odds ratio 2,8) and increased erythrocyte sedimentation rate only in women (odds ratio 2,3). Risk was decreased for patients with increasing levels of physical activity, increasing levels of alcohol consumption and use of postmenopausal estrogen (women only). When divided between ischemic and nonischemic CRVO the conditons related with a strong cardiovascular risk showed significant association with the ischemic type. Other studies have reported age, elevated lipid and cholesterol levels (Castella 1992) and diseases such as blood dyscrasias (Arend 1996, Glueck 1999, Aggio 2004), dysproteinemias, collagen vascular diseases and vasculitides (Prisco 2002) also as associated with CRVO.

Some hypercoagulability states such as activated protein C resistance (larsson 1996), factor V Leiden mutation (Gottlieb 1985), antithrombin deficiency, protein C and S deficiency, hyperhomocystinemia, 5,10-methylene-tetrahydrofolate reductase mutation (Loewenstein 1997), high lipoprotein(a) levels (Bandello 1994), tissue plasminogen activator deficiency, 4G polymorphism of plasminogen activator inhibitor (PAI-1) promoter gen, antiphospholipid antibodies (Glacet-Bernard 1994, Lureau 1995, Khamashta 1995, Wiechens 1997), factor XII deficiency (Speicher 1992), increased plasma gammaglobulin (IgA) and Waldenström's macroglobulinemia (Schwab 1960) have been mentioned in isolated studies as associated with retinal vein occlusions, however with very heterogenous results and weak evidence grade.

Regarding ocular conditions, open angle glaucoma is a well-known risk factor, even though its mechanism is not clearly understood. A theory exists that raised intraocular pressure causes external compression of central retinal vein as it passes through the lamina cribosa. This may result in turbulent blood flow distal to the constriction and subsequent thrombus formation at this level

(Foster Moore 1922). An association between CRVO and raised intraocular pressure has been described (Chew 1987), but turbulent flow is not present on Doppler studies. This is not surprising because low blood velocity, reduced vessel calibre and increased viscosity protect against turbulence (according to Reynold´s equation) and are all present in the central retinal vein when occluded. Primary open angle glaucoma or ocular hypertension have been reported in 4 to 43% of patients with CRVO (Luntz 1980).

1.3 Clinical course

The most frequent presenting symptom is an abrupt decrease in central vision and the major complications of CRVO are reduced vision resulting from macular involvement and neovascular glaucoma secondary to iris neovascularisation. Less frequently, patients may report a history of transient obscuration of vision, lasting a few seconds to minutes, with complete recovery to normal. These symptoms may recur over several days to weeks, followed by a decrease in vision or by a complete recovery of normal vision without recurrent symptoms. In both situations ophthalmoscopic evaluation typically shows scattered retinal hemorrhages in all retinal quadrants, with varying degrees of severity, usually accompanied by some engorgement of the venous system. Some patients have redness and photophobia of the involved eye. On examination, this patients manifest ciliary injection and some dilation of normal iris vessels. This occurs usually within the first days to a few weeks after the onset of visual disturbance.

Liebreich in 1855 first described the clinical appearance of CRVO as “retinal apoplexy” followed closely by Leber in 1877 who preferred “haemorrhagic retinitis”. Coats (1906) may have been the first to suggest two categories in CRVO: one with a dramatic, "blood and thunder" ophthalmoscopic appearance, loss of vision, and a poor prognosis; and the other with mild ophthalmoscopic changes, generally good visual acuity, and a relatively good prognosis. Nowadays, however, investigators rely principally on the fluorescein angiogram to assess the severity of occlusion.

The recognition of the severity of capillary occlusion is useful in predicting the clinical outcome (Williamson 1997). Thus, CRVO is usually

divided into two subtypes, ischemic (nonperfused) or nonischemic (perfused), based on clinical and angiographic evidence of the degree of retinal ischemia, as done by the Central Vein Occlusion Study Group (CVOS) in their several studies (Figure 1). However, it is impossible to categorize some eyes as either ischemic or nonischemic on the initial evaluation because retinal hemorrhages preclude adequate visualization of the capillary bed on fluorescein angiography. These unclassifiable eyes can be placed into a third category, indeterminate or hemorrhagic, and patients can be reevaluated when the hemorrhages begin to resolve during follow-up. Most of the eyes in this category, however, will develop ischemia (83% in the Central Vein Occlusion Study) on follow-up, and that is the reason why some studies consider these eyes as ischemic. Capillary nonperfusion and retinal ischemia develop in 34% of patients with CRVO. Iris neovascularisation and neovascular glaucoma may occur in 45% of ischemic CRVO and 5% of nonischemic CRVO.

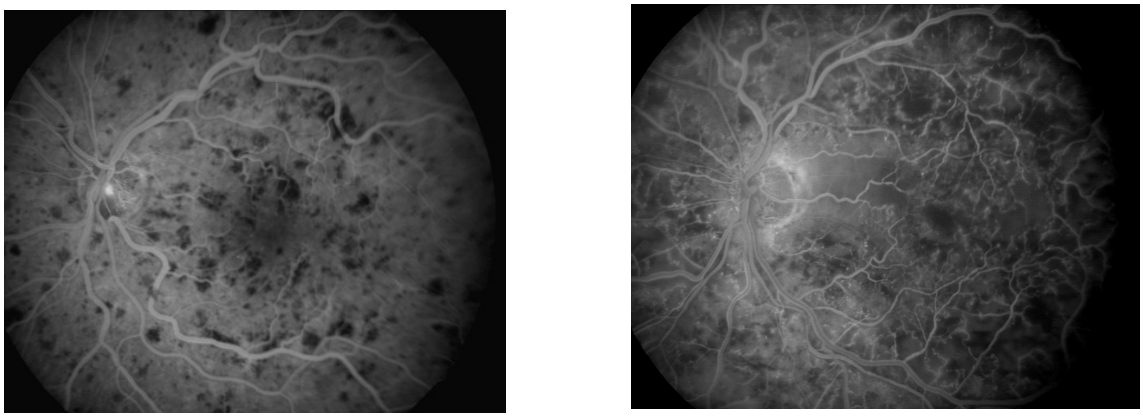

Figure 1. Angiographic images of a nonischemic (left) and ischemic (right) CRVO.

1.3.1. Nonischemic CRVO

Nonischemic central retinal vein occlusion is a much milder and more variable disease in appearance, symptoms, and course compared with ischemic central retinal vein occlusion. Patients with nonischemic central retinal vein occlusion are an average of 5 years younger (average age, 63 years) than those with ischemic vein occlusion. Complaints vary from none (i.e., condition is discovered on a routine examination) to blurred vision, which is often transient.

Visual acuity (VA) in patients with nonischemic CRVO ranges from normal to counting fingers, but the majority of patients have an initial VA of 0,4 or better. The ophthalmoscopic features are similar to those of the ischemic type but much less extensive, there is increased tortuosity and dilation of vessels and a darker appearance of the blood column. Vision may be decreased due to macular edema or macular hemorrhage. Capillary nonperfusion is initially not appreciable. Some studies have reported a lower intraocular pressure on the side of the occlusion (Chew 1987). In some series a progression from nonischemic to ischemic has been seen with an incidence between 5-22%, depending on the duration of follow-up and more often in older patients (CVOS 1993, Hayreh 1994).

The hemorrhages, vascular congestion, and engorgement gradually resolve over several months. Some patients are left with permanent cystoid macular edema, macular cystic changes, pigmentary changes, or residual microvascular abnormalities. Neovascularisation does not generally occur, and morbidity is generally limited to a persistent, mild decrease in visual acuity with a relative central scotoma. The majority of patients will have a final visual acuity of 0.4 or better.

1.3.2. Ischemic CRVO

Patients with an ischemic pattern (age average 68,5) are usually aware of a sudden, painless decrease in visual acuity. Vision ranges from 0,5 to hand movements. The onset, however, is generally not as rapid or the visual loss as extensive as in central retinal artery occlusion. Confluent hemorrhages are the most prominent ophthalmoscopic feature of an acute ischemic central retinal vein occlusion. These hemorrhages occur in a wide variety of shapes and sizes; they are usually concentrated in the posterior pole, but may be seen throughout the retina. Hemorrhages in the superficial retina may be so prominent about the posterior pole that the underlying retina is obscured. Many hemorrhages are flame shaped, reflecting the orientation of the nerve fibers. Near the disc the hemorrhages usually appear with a radial pattern. Dot and punctate hemorrhages are interspersed and indicate involvement of the deeper retinal layers. Bleeding may be extensive, erupting through the internal limiting

membrane to form a preretinal hemorrhage or extending into the vitreous. Small dot hemorrhages may be seen either isolated or clustered around small venules. The entire venous tree is tortuous, engorged, dilated, and dark. The retina is edematous, particularly in the posterior pole; some of this edema may obscure portions of the retinal vessels. Cotton-wool patches (soft exudates) are often present. The disc margin is blurred or obscured, the physiologic cup is filled and the venous pulse is absent. Vision depends primarily on the extent of macular involvement.

The intravenous fluorescein angiogram pattern of an ischemic central retinal vein occlusion is usually characterised by a delayed filling time of the venous tree of the retina, capillary and venous dilation, and extensive leaking of fluorescein into the retina, particularly in the macular area and in the area adjacent to the larger venous trunks and capillary nonperfusion (Laatikainen 1976) (Figure 2). Microaneurysms may not be noted at the time of initial occlusion, but are usually manifest shortly thereafter. Late-phase fluorescein images show the non perfusion of the capillary bed as patchy extravascular areas of fluorescence leckage and staining of the retinal veins.

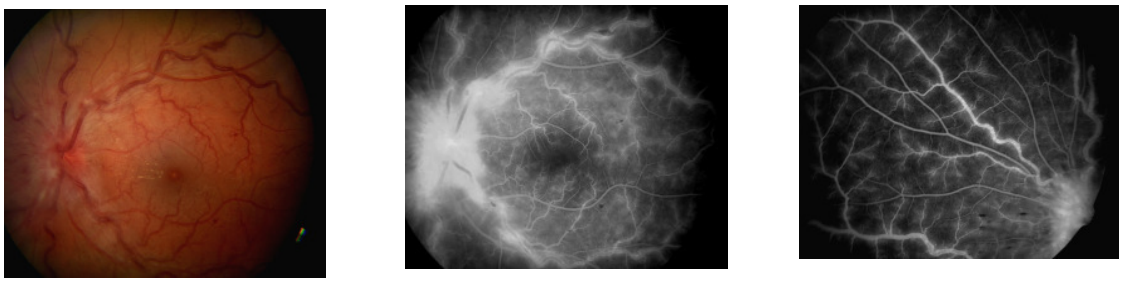

Figure 2. Fundus appearance and late phase angiography of an ischemic CRVO six months after onset.

The prognosis for ischemic central retinal vein occlusion is generally poor because of decreased visual acuity and neovascularisation. Visual loss occurs because of macular edema, capillary nonperfusion, overlying hemorrhage (either retinal or vitreal), or a combination of all of these. Retinal edema usually gradually subsides except in the macula, where it may persist for many months or years.

In the chronic phase, most hemorrhages gradually disappear over many months. Prominent venous loops, which are collateral communications (chorioretinal anastomosis), may be observed on the surface of the disc. These loops develop within 3 to 14 months after occlusion from the existing retinal vasculature and are collateral vessels between the obstructed disc capillaries and the unobstructed choroidal capillaries.

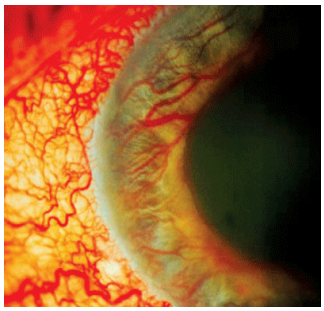

Figure 3. Rubeosis iridis.

The most serious complication of central retinal vein occlusion, both ischemic and nonischemic, is neovascularisation. Neovascularisation of the retina or optic disc occurs less frequently than neovascularisation of the iris, and usually only in ischemic occlusions (Evans 1993). The reason of the low incidence of retinal surface neovascularisation in ischemic central retinal vein occlusion will be discussed in the next chapter. Neovascularisation of the iris and frequently neovascular glaucoma occurs in approximately 8% to 25% of all central retinal vein occlusions and generally only in those eyes that exhibit an ischemic pattern of occlusion (Magargal 1981). The incidence of anterior segment neovascularisation in nonischemic central retinal vein occlusion is approximately 5%, compared with approximately 45% for ischemic central retinal vein occlusion (CVOS 1997). Neovascularisation of the iris or angle (Fig. 3) is significantly correlated with the extent of capillary nonperfusion on the fluorescein angiogram. Neovascularisation of the iris may develop as early as 2 weeks after central retinal vein occlusion or as late as 2 ½ years, in almost all patients within the first year, but usually in the first 3 months (Hayreh 1983).

The relative afferent pupil defect has been seen by some experts as an important feature in ischemic CRVO (Bloom 1993). Hayreh (Servais 1986) and associates believe that relative afferent pupil defect is the most reliable test to detect ischemia in patients with unilateral disease. This remain a controversial topic and we have not evaluated it in our patients.

Besides having the complications already discussed, patients with central retinal vein occlusion are also at risk for vascular occlusion in the contralateral eye. Approximately 7% to 11% of patients can be expected to have a bilateral

nonsimultaneous central retinal vein occlusion (The Eye Desease Case-Control Study Group 1996). Occasionally a patient will have a simultaneous occlusion of both the central retinal vein and the central retinal artery (Brown 1993). Unlike patients with only a central retinal vein occlusion, these patients often have some retrobulbar pain, and vision may be decreased to no light perception. The retina appears pale, with a cherry-red spot in the macula. Disc edema and retinal hemorrhage may be present. Simultaneous occlusion of the central retinal vein and the cilioretinal artery (Keyser 1994, Mennel 2005) or a branch retinal artery have been reported in a few patients (Duker 1990).

To sum up, we can say that the ischemic form of CRVO presents a much worse natural course with greater loss of vision, greater risk of secondary glaucoma and consequent painful eye and the aesthetic problem of a chronic red eye and strabismus.

1.4. Physiopathology and histology

The pathogenesis of CRVO and the underlying histopathology have remained controversial ever since Michel in 1878, who found a thrombus in one patient studied, first correlated the clinical appearance with the histopathology. Many of his contemporaries believed that stagnation in the central retinal artery caused secondary thrombosis and obstruction of the central retinal vein. Arguing against the presence of thrombosis, Verhoeff (1906) reviewed 39 cases in the literature and concluded that only two had pathological evidence of thrombosis. He believed that the blockage was due to a venous channel dissecting through intimal thickening of the wall of the vein, a finding however which he also found in patients with glaucoma. Some felt at this time that congenital vascular
anomalies caused CRVO while collateral venous channels were protective. The fact that relatively few eyes have been histopathologically examined during the freshly obstructed stage has contributed to the problem. Many of the reported cases involved eyes that were enucleated because of longstanding neovascular glaucoma and secondary changes that did not play a role in the original occlusion.

Pathological evidence of removed eyes (Green 1981) have shown an occlusion at or just behind the lamina cribosa, a location where the central retinal artery and vein are narrower, share an adventitial sheath and their expansion and displacement are limited (Fig. 4). These anatomical conditions probably coexist with systemic and hemodynamic factors that lead to occlusion in many patients.

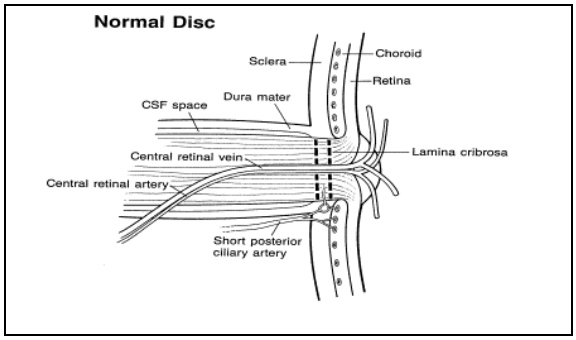

Figure 4. Anatomy of posterior pole and optic nerve.

Green and co-workers studied 29 eyes that were enucleated 6 hours to 10 years after occlusion. As a result of this study, they hypothesised that the flow of blood through the central retinal vein becomes increasingly turbulent as the vein progressively narrows at the lamina cribrosa, where it also may be further impinged upon by arteriosclerosis of the adjacent central retinal artery. This turbulence damages the endothelium in the retrolaminar vein, which exposes collagen and initiates platelet aggregation and thrombosis. Endothelial cell proliferation and recanalisation of the vein may often occur as a reparative event. Years later, a thick-walled vein with a single channel may occur (phlebosclerosis). In some eyes an adjacent, partially obstructed, or narrowed central retinal artery has been observed. This observation is consistent with the prevailing clinical impression that the principal condition associated with retinal vein occlusion is arteriosclerosis. There is an increased incidence of generalized atheromatous disease in patients who have a central retinal vein occlusion. As part of this atheromatous change, sclerosis occurs in the common adventitia, which encircles both central retinal artery and vein within the rather rigid support structure of the lamina cribrosa (Fig. 5).

Hayreh and co-workers (Hayreh 1966) have investigated the role of occlusion of the central retinal vein and central retinal artery in an animal model. They attempted to produce central retinal vein occlusion in healthy young monkeys by diathermy of the central retinal vessels in the orbit near their entry into the optic nerve sheath. Their study showed that occlusion in the orbit of the central retinal vein alone produced mildly engorged and tortuous vessels and a few retinal hemorrhages; all of these conditions returned to normal in approximately 2 weeks. However, when both the central retinal vein and the central retinal artery in the orbit were obstructed simultaneously, a fundus appearance was produced that was "entirely characteristic" of central retinal vein occlusion. Later, histopathologic examination of these eyes showed a hemorrhagic infarct of the inner retinal layer. Hayreh and co-workers concluded from these experiments that concomitant arterial occlusion is essential in the production of an ischemic central retinal vein occlusion, although its occurrence is possibly only transient, and that the site of occlusion is important in determining both the severity and type of occlusion. However, this model of occlusion in the orbit of healthy young monkeys is probably not comparable to the situation in the aging human, whose occlusion is located at or just posterior to the lamina cribrosa and ignored the influence of collateral venous channels around the nerve.

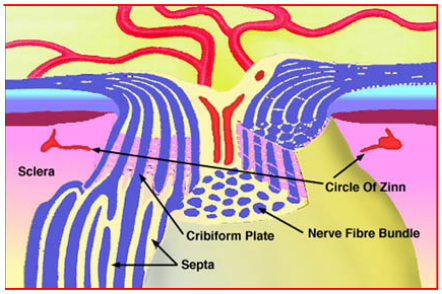

Figure 5. Lamina cribosa and adjacent structures.

Therefore, Fujino and associates (Fujino 1969) injected Neoprene into owl monkeys to occlude the vein at the optic nerve head. They were able to show that a primary and complete occlusion of the central retinal vein at the disc produces a secondary artery insufficiency. The ophthalmoscopic appearance produced in monkeys, however, is not identical to the appearance of central retinal vein occlusion in humans. This may be because this technique obstructs all of the branch retinal vessels in the peripapillary region, which, in turn, may preclude collateralization.

Color Doppler ultrasound has shown, as might be expected, that the venous velocity in the eye of a patient with central retinal vein occlusion is markedly reduced compared either with the unaffected eye or to control eyes, particularly within 3 months of onset of occlusion (Williamson 1994). There is evidence, however, that the central retinal artery blood flow is also impaired in eyes with acute central retinal vein occlusion (Arsène 2002).

The retinal pathology in an ischemic central retinal vein occlusion (Fig. 6) consists of a hemorrhagic infarction of the retina that affects primarily the inner retinal layers (Kornzweig 1964). Neovascularisation of the iris and anterior chamber angle can develop; less frequently, retinal neovascularisation can also occur. Later changes include thickening of the retina and reactive gliosis. The low incidence of retinal surface neovascularisation in ischemic central retinal vein occlusion is thought to be due to the destruction of endothelial cells, which provide the source for endothelial proliferation and neovascularisation (Chan 1979).

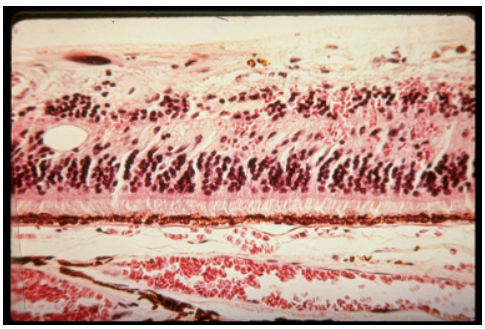

Figure 6. Histopathologic examination of an eye with CRVO reveals hemorrhages throughout all layers of the retina with diffuse areas of hemorrhagic infarction and ischemia

1.5. Treatment

A wide variety of therapeutic agents have been used to treat central retinal vein occlusion and its complications: topical administration of potassium iodide and pilocarpine (Braendstrup 1950), anticoagulants, fibrinolytic agents, hyperosmotic agents, CO_2 inhalation (Gombos 1978), cholesterol-lowering agents (Clements 1968), vitamins, corticosteroids, prostacyclin (Zygulaska-Mach 1980), aspirin, ticlopidine (an inhibitor of platelet aggregation), isovolemic hemodilution, acetazolamide, traditional Chinese medicine (Zhang 1983), x-rays (Gradle 1937, Hessberg 1944), vascular endothelial growth factor (VEGF) inhibitor and surgical and laser procedures.

Treatment of an underlying systemic condition, if one is found, is indicated, although only rarely will this reverse the vein occlusion. However, treatment of an underlying systemic medical condition might help to prevent the opposite eye from developing a vascular occlusion. In a first examination, intraocular pressure should be tested and carotid bruits auscultated in case of ocular ischaemic syndrome. For the latter, colour Doppler imaging of the orbit and carotid arteries should be performed when suspicion is high (Brown 1984). Laboratory tests of predisposing medical conditions are worth investigating routinely because the recurrence rate of CRVO may be reduced if general medical conditions are treated.

1.5.1. Medical treatment

1.5.1.1. Anticoagulation

In 1938, Holmin and Ploman (Holmin 1938) introduced anticoagulant therapy. Since then, some authors have claimed varying degrees of success. Some investigators have found that either heparin or warfarin, or a combination, is effective in improving visual acuity after a central retinal vein occlusion (Klein 1950, Vannas 1966); others have found no beneficial effect (Cassady 1953) and there are also reports on persons who developed CRVO while being treated with Coumadin (Mruthyunjaya 2006). Anticoagulants act by preventing

fibrin formation, but there is no reason to believe that they would be effective in dissolving the thrombosis once it has occurred. They may, however, prevent propagation of the thrombus and indirectly facilitate spontaneous thrombolysis. Although some studies have suggested that anticoagulation does reduce the incidence of neovascular glaucoma (Duff 1951), as yet a randomised clinical trial of anticoagulation has not been performed. The disadvantages of anticoagulation include significant ocular and systemic bleeding complications. Anticoagulation might be targeted to patients with specific thrombogenic abnormalities such as APC resistance.

1.5.1.2. Fibrinolysis

In a small, randomised clinical trial, streptokinase (a fibrinolytic agent) has been shown to have a beneficial effect on visual outcome in central retinal vein occlusion (Kohner 1976). Unfortunately, vitreous hemorrhage is a serious complication of this method of treatment and therefore limits its usefulness. In later studies (Hattenbach 1999), recombinant tissue plasminogen activator (rtPA) has been systemically administrated and intravitreal and subretinal injected (Lam 2002) without major complications but it can not be stated that patients benefit from this treatment. Weiss (Weiss 2001) has reported the cannulation of a retinal vein and direct injection of rTPA with good results in case series, however other authors report technical difficulties and no significant benefit.

1.5.1.3. Hemodilution

Some authors have advocated the use of hemodilution, claiming some improvement in visual acuity in nonischemic CRVO (Hansen 1989, Glacet-Bernard 2001). However, in ischemic occlusions there are contradictory claims (Wolf 1994). There is not much scientifically valid evidence of the beneficial effects of this therapy.

1.5.1.4. Corticosteroids

The increase in retinal capillary permeability and subsequent retinal edema that often occur in the course of CRVO may be the result of a

breakdown of the blood-retinal barrier, possibly mediated in part by vascular endothelial growth factor (VEGF) (Pe'er 1998). Corticosteroids have been demonstrated to abolish the induction of VEGF by the pro-inflammatory mediators platelet-derived growth factor and platelet-activating factor in a time- and dose dependent manner (Bynoe 2003, Blumenkranz 2005). In nonischemic CRVO, as mentioned above, macular edema is one of the main causes of decrease of visual acuity and there is evidence that oral or intravitreal corticosteroids may help to reduce macular edema and improve visual acuity in some cases (Ip 2004, Bashshur 2004). In addition, it has been reported that inflammatory cell infiltrates are present in the area of the thrombotic occlusion in up to 48.3% patients, including 34.0% with lymphocytic infiltration within the thrombus (Green 1981). Perhaps steroids may have an effect not only on macular edema but also on both the thrombus and the optic nerve. The fact that intavitreal triamcinolone is being used off-label and that complications such as frequent cataract formation, frequent increased intraocular pressure (Jonas 2003, Smithen 2004) and endophthalmitis (Moshfeghi 2003) and have been reported must be clearly weighed in the therapeutical decision.

1.5.1.5. Carbonic anhydrase inhibitor

Systemic Acetazolamide (Diamox®) is a carbonic anhydrase inhibitor used in different types of macular edema and may help to reduce macular edema associated with CRVO and improve visual acuity in some patients.

1.5.1.6. Vascular endothelial growth factor (VEGF) inhibitor

Retinal vein occlusion is associated with increased intravitreal levels of VEGF (Aiello 1994), particularly in cases complicated by neovascularisation (Pe'er 1995). Inhibition of VEGF by antisense oligodeoxynucleotide (Bhisitkul 2005) or anti-VEGFmonoclonal antibody (Adamis 1996) resulted in reduction or complete prevention of iris neovascularisation in animal models of CRVO. A recombinant humanized monoclonal antibody directed against VEGF, available (bevacizumab, Avastin®, Genentech) for cancer therapy, is being used off-label to treat macular edema secondary to CRVO. First reports on this therapy describe a significant decrease in macular edema and improvement in visual

acuity (Iturralde 2006, Jaissle 2006). However the number of patients and the follow-up of these studies are limited and it is unknown how often re-injections are needed.

1.5.1.7. Photocoagulation

Photocoagulation is the accepted treatment of some forms of ischemic central retinal vein occlusion (Osborne 2004). Clinical trials in the past have shown that it does not affect the final visual acuity outcome, but is effective in both the prevention and the regression of neovascularisation (Magargal 1982). It is effective in causing the regression of neovascularisation of the disc (NVD), neovascularisation elsewhere (NVE), and neovascularisation of the iris, as long as they are not already in an advanced state.

1.5.1.7.1. Panretinal photocoagulation

Prophylactic panretinal photocoagulation in high-risk eyes has been reported to be effective in preventing neovascular glaucoma (Laatikainen 1983). Magargal and co-workers used panretinal photocoagulation prophylactically in a nonrandomised series of 100 consecutive patients with ischemic central retinal vein occlusion. Neovascular glaucoma developed in only two patients in this group after treatment, and both patients had another ischemic event that occurred after treatment. With no treatment, approximately 45% of these patients would be expected to have developed neovascular glaucoma. However, a randomised, prospective, controlled clinical trial has been performed by the Central Vein Occlusion Study Group (CVOS 1995) to determine wether prophylactic panretinal photocoagulation in ischemic central retinal vein occlusion prevents the development of iris or angle neovascularisation, or whether it is more appropriate to apply panretinal photocoagulation only when such neovascularisation develops. In this study, eyes with central retinal vein occlusion and at least 10 disc diameters of nonperfusion were randomly assigned to either an immediate prophylactic panretinal photocoagulation group (early treatment) or to a delayed panretinal photocoagulation group (no early treatment) that received photocoagulation only if neovascularisation subsequently developed. Neovascularisation

developed in 20% of the eyes in the early-treatment group compared with 35% in the no-early-treatment group, a difference that was not statistically significant. Most patients had regression within the first 3 months of neovascularisation after panretinal photocoagulation was administered when the rubeosis was detected, but 11% had persistent neovascularisation that regressed over many months. As a result of this study, the Central vein Occlusion Study Group recommends the performance of panretinal photocoagulation promptly at the first sign of definite neovascularisation, but not prophylactically.

The most important risk factor for predicting the occurrence and extent of anterior segment neovascularisation in this study was the amount of nonperfused retina. Other risk factors that correlated individually with neovascularisation were visual acuity, duration of occlusion of less than 1 month, moderate or severe venous tortuosity, and retinal hemorrhages greater than a standard photography. Neovascularisation, when it developed, usually did so within the first 3 months after randomisation into the study.

1.5.1.7.2. Macular grid photocoagulation

The Central Retinal Vein Occlusion Study Group also performed a randomized, prospective clinical trial in 1995 on the effect of macular grid photocoagulation compared with no treatment on eyes with 0,4 or worse visual acuity due to macular edema with no capillary nonperfusion on fluorescein angiography. Although grid photocoagulation lessens macular edema both angiographically and clinically, there was no difference in visual acuity between the treated and untreated patients. For treated patients, there was a trend toward decreased visual acuity in patients older than 60 years and visual improvement in patients younger than this; this effect was not seen in untreated patients. Although this study suggests a possible benefit to visual acuity in younger patients with macular edema who are treated compared with untreated controls, the number of patients in this subgroup is too small for a statistically valid comparison of treated versus untreated eyes.

1.5.2. Surgical treatment

Surgical decompression of the central retinal vein was first advocated by Vasco-Posada (Vasco-Posada 1972), who cut the scleral ring and adjacent part of the dural sheath of the optic nerve. Since then many surgeons have tried similar tecniques (Arciniegas 1984, Dev 1999, Stoll 1988).

McAllister and Constable (McAllister 1995) reported a surgical technique to create a chorioretinal anastomosis in patients with nonischemic central retinal vein occlusion. It was to rupture Bruch's membrane first in an area adjacent to the edge of a vein located at least three disc diameters from the optic disc with the argon laser; they then used a YAG laser to create a small opening in the sidewall of the adjacent vein. Nevertheless, this technique and others based on the same principle of inducing chorioretinal anastomosis have been presented in the literature by several groups with heterogenous results (Fekrat 1998, Fekrat 1999, Mirshahi 2005). McAllister´s procedure is by no means benign and there is a risk of significant complications (particularly subretinal, choroidal and from the retinal vein hemorrhages) (Aktan 1998). These complications heavily outweigh the benefits from this technique (Tang 2000).

Opremcak et al (Opremcak 2001) have described an operation involving a standard three-port pars plana vitrectomy and radial incision on the nasal side of the optic nerve based on the hypothesis of a neurovascular compression syndrome of the central retinal artery, central retinal vein and optic nerve head to occur within the confined space of the scleral outlet. Radial optic neurotomy (RON) was thought to improve blood flow by relieving pressure on the vein. More recently, however, it has been reported that new chorioretinal shunts induced by RON may drain the retinal circulation to the choroid improving the blood flow. Some experts have also pointed out the need for randomized studies to evaluate the effect of vitrectomy alone without RON since the vitreous extraction may improve the oxygenation of the retina and its metbolical exchange with the vitreous cavity (Stefansson 1990, Hikichi 1995). Thus, the efficacy of RON is controversial and its effect on the retinal blood flow is now being investigated by some authors.

2. HYPOTHESIS

The surgical technique consisting in pars plana vitrectomy and radial optic neurotomy is an effective and safe therapy for the occlusion of central retinal vein and improves the long-term outcome compared with conservative treatment.

3. OBJECTIVES

1. To compare the functional and anatomical results of surgical (radial optic neurotomy) and conservative treatment in patients with CRVO.
2. To measure the influence of chorioretinal anastomosis on visual outcome and blood flow.
3. To analyse the safety of RON.

4. MATERIAL AND METHODS

Between 2002 and 2005, 63 eyes of 63 consecutive patients with CRVO were seen in the University Eye Clinic in Marburg and enrolled this study. The first visit was less than 2 months after the onset of CRVO in all patients. We divided them into 2 groups: 28 (44,5%) patients in group A and 35 (55,5%) in group B. Patients in group A underwent a surgical approach with pars plana vitrectomy and radial optic neurotomy while those in group B were handled with a conservative therapy.

4.1. Inclusion criteria

Patients in group A were elegibled for RON since they had severe CRVO with preoperative best corrected Snellen visual acuity of 0,3 or worse and a duration of the symptoms no longer than 3 months. All patients gave their informed consent for the surgical procedure in accordance with the Helsinki declaration after being explained about the current experience with the procedure, its risk and the limited therapeutical options.

In group B we included patients with best-corrected visual acuity (BCVA) better than 0.3 and those patients who refused the surgical treatment.

4.2. Epidemiological characteristics

Patient data are summerized in table 1. Average age in group A was 67,4 ±9,1years and in group B 65,5 ±14,5 years. There were more men in the study than women: sixteen (57,2%) men and twelve (42,8%) women in group A, nineteen (54,3%) men and sixteen (45,7%) women in group B.

Fifeteen (53,6%) patients in group A and nineteen (54,3%) in group B had some evidence of hypertension, either diastolic blood pressure of 90 mmHg or higher or systolic blood pressure of 160 mmHg or higher.

Ten (35,7%) patients in group A and ten (28,6%) patients in group B had diabetes mellitus.

In group A 8 (28,6%) patients had elevated lipid or cholesterol levels, 7 (30,4%) patients had cardiovascular or peripheral vascular disease. In group B 9 (25,7%) patients had dyslipidemia, 10 (31,2%) patients had cardiovascular or peripheral vascular disease, 1 had relative poliglobulia, 1 had activated protein C resistance, 1 had high levels of homocystein and 1 was undergoing VIOXX® (rofecoxib) therapy[1].

At the time of onset of the venous occlusion, as patients came to our clinic, they were hospitalised, followed a standard therapy and underwent a medical screening to detect any of the ophthalmic and systemic conditions that may represent a risk factor mentioned above. The therapy consisted of isovolemic hemodilution (only if hematocrit > 40%, with a goal of 33-38%), which was performed in 11 (39,3%) patients in group A and 9 (25,7%) patients in group B, anticoagulant therapy with heparin in 13 (46,4%) patients in group A and in 12 (34,3%) patients in group B, systemic acetazolamide (Diamox) in 3 (10,7%) patients in group A and one (2,8%) in group B.

	group A	group B
Gender	♀ 12 (42,8%) ♂ 16 (57,2%)	♀ 16 (45,7%) ♂ 19 (54,3%)
Age	67,4 (±9,1)	65,5 (±14,5)
Hypertension	15 (53,6%)	19 (54,3%)
Diabetes mellitus	10 (35,7%)	10 (28,6%)
Vascular disease	9 (32,1%)	13 (37,1%)

Table 1. Baseline epidemilogical characteristics and systemic risk factors.

4.3. Pre- and postoperative evaluation

Best corrected Snellen visual acuity (VA), intraocular pressure (IOP), slit-lamp inspection of the anterior segment, dilated fundus examination with indirect ophthalmoscopy, fundus photography, fundus fluorescein angiography (FA) and measurement of time of arteriovenous transit on FA were performed on the first visit and one year after surgery in the RON group (A) and preoperatively and one year after onset in patients with conservative treatment (B). On the six-month control FA and measurement of time of arteriovenous transit were not performed. FA and fundus photographies were taken with a FF450 plus IR fundus camera from Carl Zeiss Meditec AG and processed with Zeiss VISUPAC Digital Imaging System

4.4. Ophthalmologic characteristics

4.4.1. Visual acuity

Best corrected Snellen visual acuity at the first visit ranged in group A from 0,0125 to 0,30 with a mean of 0,10 and from 0,016 to 0,8 with a mean of 0,23 in group B.

Classifying eyes as done by the CVOS (Table 2), who proved that VA at baseline was the main predictor of visual outcome after 3 years, we had in group A 14 (50%) eyes with initial VA worse than 0,1 and 14 (50%) eyes with initial VA between 0,1 and 0,4. In group B, also at baseline 9 (25,7%) eyes had a VA worse than 0,1, 18 (51,4%) eyes and 8 (22,9%) had a VA better than 0,4.

Table 2. Distribution of initial VA.

	Group A	Group B
<0,1	50%	25,7%
0,1-0,4	50%	51,4%
0,4<	0%	22,9%

4.4.2. Intraocular pressure

Mean IOP in eyes in group A was 14,9 mmHg and 15,6 mmHg in group B.

4.4.3. Fundus hypertonicus

Funduscopy revealed hypertonicus signs in seven (25%) patients in group A and eight (22,8%) patients in group B.

4.4.4. Glaucoma

In group A five (17,8%) patients had open-angle glaucoma and in group B six (17,1%) patients had been diagnosed with open-angle glaucoma. One patient in group A had developed a neovascular glaucoma by the time of our first control.

4.4.5. Previous vascular occlusion

Two (7,1%) patients in group A had a previous venous occlusion in the fellow eye (one CRVO and one branch retinal vein occlusion). In group B, three (8,6%) patients presented previous vascular occlusion on the eye: one patient had a previous branch retinal vein occlusion in the same eye, another patient had a CRVO in the fellow eye, and the third had a branch retinal artery occlusion in the fellow eye.

4.4.6. Iris neovascularisation

Two (7,1%) patients in group A presented iris neovascularisation, one of them mentioned above with neovascular glaucoma. In group B four (11,4%) eyes had iris neovascularisation on the first control.

Table 3. Baseline ophthalmologic characteristics

	group A	group B
VA	0,10	0,23
IOP (mmHg)	14,9	15,6
Fundus hypertonicus	7 (25%)	8 (22,8%)
Open-angle glaucoma	5 (17,8%)	6 (17,1%)
Previous vascular occlusion	2 (7,1%)	3 (8,6%)
Iris neovascularisation	2 (7,1%)	4 (11,4%)

4.4.7. Retinal perfusion

An essential issue in this study was the appropriate measurement of retinal perfusion. Thus, each angiography was independently analized by two experienced retinal experts following the *Central Vein Occlusion Study Group* recommendations: eyes were defined as ischemic if they had at least 10 dics areas of retinal capillary nonperfusion, nonischemic if they had angiographically less than 10 disc areas of nonperfusion and hemorrhagic if the retinal perfusion could not be evaluated due to extensive hemorrhage (Figure 7).

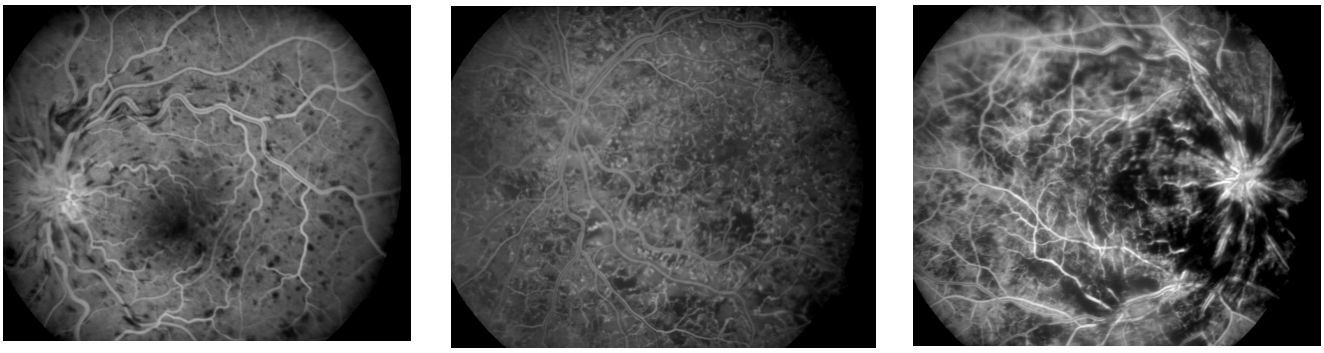

Figure 7. Example of nonischemic (left), ischemic (middle) and hemorrhagic (right) CRVO.

4.4.8. Time of arteriovenous transit

To quantify the impairment of retinal perfusion we measured the time of arteriovenous transit using standard fluorescein angiography with one frame per second in the early phase. The concentration of fluorescein was estimated with a grey scale.

After FA was performed with FF450 plus IR fundus camera from Carl Zeiss Meditec AG and processed with Zeiss VISUPAC Digital Imaging System we proceeded to the perfusion quantification. We used Adobe Photoshop® version 9.0 CS2. Firstly, a ring was designed for each patient with a diameter of 2,5 optic disc in order to measure the intensity in the vessels always at the same site (Fig. 8). Then we calculated the time until maximal fluorescence intensity in the arterial phase (aT_{max}) and in the venous phase (vT_{max}), and the interval between both times represented the retinal circulation duration time ($\Delta T_{max} = vT_{max} - aT_{max}$)[2].

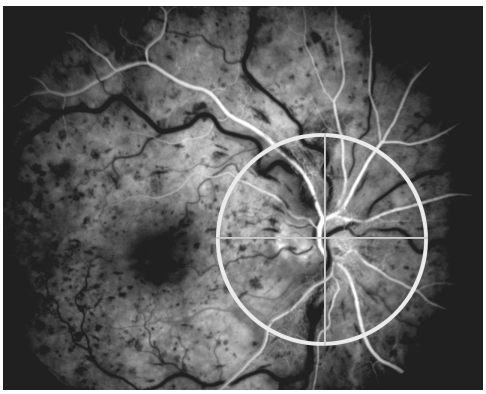

Figure 8. Arterial phase of angiography with our ring.

4.4.9. Chorioretinal anastomosis

Another crutial element in our investigation was to determine the development of chorioretinal anastomosis (CRA). Histological studies have shown that the central retinal vein may become permanently narrowed after an intraluminal thrombus has recanalised (Green 1981). Several studies have pointed out the benefitial effect of the surgically induced chorioretinal anastomosis, that may bypass the occlusion and improve retinal perfusion (Quiroz-Mercado 2001). It has been hypothesised that this bypass is not likely to lead to reperfusion of the periferic areas with retinal capillary dropout but to keep the perifoveal area perfused and as a result to achieve some visual improvement (Remky 1997). In addition, the iatrogenic shunt induction may reduce the likelihood of the development of

neovascularisation (Takahashi 1998). The presence of CRA was determined clinically and angiographically.

4.5.Surgical procedure

Pars plana vitrectomy with radial optic neurotomy was performed in each patient as previously described. We operated only after a complete explanation of the surgical procedure and its risks and the consequent informed consent from each patient was done. The vitrectomy was performed with an Accurus® vitrectomy system from Alcon®. After removal of complete vitreous, indocianine green was applied with a fluid needle in the fluid-filled eye and the internal limiting membrane was peeled (Schmidt 2003).

Afterwards, a site on the nasal edge of the optic disc that avoided the major retinal vessels (Fig. 9) was chosen using the preoperative fluorescein angiography. The nasal side was also targeted to avoid damage to the maculopapillary nerve fibers, and the neurotomy was made in a radial fashion to avoid transecting nerve fibers. A 20-gauge microvitreoretinal blade was used, cutting an equal portion of the cribiform plate and adjacent sclera, the blunt side of the blade was inserted towards the optic disc centre and the sharp side towards the retinal side to a depth of 2,5 mm. Intraocular pressure was raised if there was evidence of any bleeding.

Figure 9. Site of the neurotomy on the nasal edge of the optic disc.

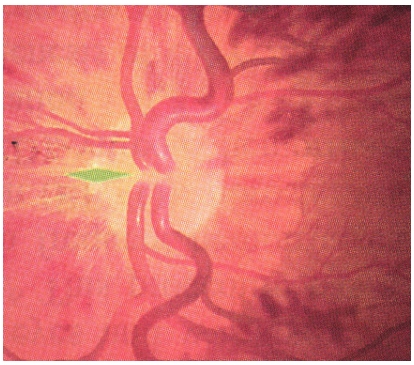

4.6. Statistics

The data obtained were analysed with frequency and descriptive statistics. Because Snellen charts were used to measure vision for both groups, the visual acuities were converted to logMAR units to perform the appropriate statistical manipulation. To compare the VA and other parameters between the two study groups the Mann-Whitney U test was used. For the analysis of these parameters pre- and postoperative within each group the Wilcoxon ranked test was used. All data were retrospectively analized using SPSS statistical software for Windows (SPSS Version 11.0.1; Chicago, IL, USA).

Data are provided as mean ± SD. Values of $P < 0,05$ were considered to be statistically significant.

5. RESULTS

A total of 63 eyes were enrolled in our study. Regarding clinical conditions patients underwent a surgical (group A) or conservative (group B) therapy. Twenty-eight patients were in group A and thirty-five in group B. Patients´ age ranged from 50 to 83 years (mean 67,4 years) in group A and from 25 to 93 years (mean 65,5 years) in group B. Of the 28 patients in group A, 16 (57,2%) were men and 12 (42,8%) were women while in group B we had 19 (54,3%) men and 16 (45,7%) women. In group A the duration of visual loss before surgery varied from 6 days to 3 months (mean 25 days). Five patients in group A and six patients in group B had an open-angle glaucoma, 2 patients in group A and 3 in group B had a previous vascular occlusion, 7 patients in group A and 8 patients in group B had a fundus hypertonicus and 2 patients in group A and 4 patients in group B had an iris vascularisation by our first control (Table 4). Fifeteen patients in group A and 19 in group B had a relevant medical history of arterial hypertension, 10 patients in each group had a diabetes mellitus and 9 patients in group A and 13 in group B presented a vascular disease (Table 5).

Follow-up period was 1 year with at least one visit six months and one year after surgery in group A or six months and one year after the beginning of the conservative therapy in group B.

Table 4. Baseline ophthalmologic risc factors

	group A	group B
Fundus hypertonicus	7 (25%)	8 (22,8%)
Open-angle glaucoma	5 (17,8%)	6 (17,1%)
Previous vascular occlusion	2 (7,1%)	3 (8,6%)

Table 5. Baseline systemical risc factors

	group A	group B
Arterial hypertension	15 (53,6%)	19 (54,3%)
Diabetes mellitus	10 (35,7%)	10 (28,6%)
Syst. vascular desease	9 (32,1%)	13 (37,1%)

5.1. Visual acuity

Preoperative best-corrected visual acuity ranged from 0,0125 to 0,3 (logarithm of the minimum angle of resolution [logMAR], 1,9 to 0,5) with a mean of 0,10 (logMAR 1,0) in group A and from 0,016 to 0,8 (logMAR 1,8 to 0,1) with a mean of 0,23 (logMAR 0,64) in group B. As seen in Table 6, the postoperative best-corrected visual acuity ranged six months after surgery in group A from 0,025 to 0,63 (logMAR 1,6 to 0,2) with a mean of 0,17 (logMAR 0,8) and from 0,016 to 1,0 (logMAR 0,8 to 0,0) with a mean of 0,3 (logMAR 0,5) in group B. One year after surgery, VA ranged in group A from 0,04 to 1,0 (logMAR 1,4 to 0,0) with a mean of 0,23 (logMAR 0,64) and in group B it ranged from 0,016 to 1,0 (logMAR 1,8 to 0,0) with a mean of 0,28 (logMAR 0,54).

Table 6. Progression of the visual acuity (mean ± SD)

	group A	group B
Pre OP	0,10 ±0,03	0,23 ±0,11
6 months	0,17 ±0,10	0,30 ±0,14
12 months	0,23 ±0,12	0,28 ±0,16

In the RON group we observed a continuous visual improvement from a mean value of 0,10 to 0,23 one year after surgery. Whereas, visual acuity raised in group B from 0,23 to 0,28. The increase in visual acuity was statistically significant only in group A (Fig. 10a).

Figure 10a. Evolution of VA for group A (RON) and group B (control).

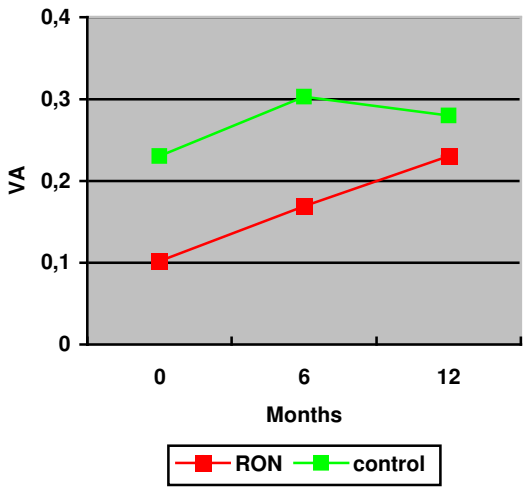

Expressed in Snellen lines as in figure 10b, group A achieved a mean gain of 2,51 logMAR units and group B a mean gain of 0,6 logMAR units.

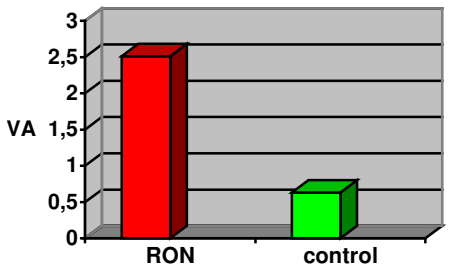

Figure 10b. Visual increase expressed in logMAR units

In group A, among the 14 patients with initial VA worse than 0,1, one year postoperative 8 (57,1%) remained under 0,1, 5 (35,8%) presented a VA between 0,1 and 0,4 and 1 (7,1%) achieved a final VA of 0,5 or better. In the next group of patients, those with preoperative VA between 0,1 and 0,4, 1 (7,1%) patient worsened to less than 0,1, 6 (42,9%) remained between 0,1 and 0,4 and 7 (50%) showed an increase to 0,5 or better final VA.

If we analyse the initial visual acuity regarding retinal perfusion (Table 7), we see in group A an intial mean BCVA of 0,13 for nonischemic eyes, 0,12 for ischemic eyes and 0,10 for hemorrhagic eyes. On the other hand, in group B nonischemic eyes had an intial mean BCVA of 0,36, ischemic eyes had a mean BCVA of 0,11 and hemorrhagic eyes of 0,5.

Table 7. Initial Snellen visual acuity correlated with initial retinal perfusion status

	Group A	Group B
Nonischemic	**0,13**	**0,36**
Ischemic	**0,12**	**0,11**
Hemorrhagic	**0,10**	**0,50**

One year later, the visual improvement was 2,51 logMAR units for group A and 0,63 logMAR units for group B (Table 8). This improvement was statistically significant ($p<0,05$) only in group A. In this group A when subdivided regarding retinal perfusion, the nonischemic group showed a gain of 2,50 logMAR units, the ischemic group of 1,66 logMAR units and the hemorrhagic group had an improvement of 2,97 logMAR units.

Table 8. Mean increase of VA expressed in logMAR units one year after treatment.

	Group A (n=28)	Group B (n=35)
All	2,51	0,63
Nonischemic	2,50	0,58
Ischemic	1,66	0,44
Hemorrhagic	2,97	0,66

In group A, among eyes that presented an improvement of 3 or more logMAR units we could observe a majority of hemorrhagic eyes (55%), followed by ischemic eyes (27%). Nonischemic eyes represented 18% of all of these eyes (Fig. 11).

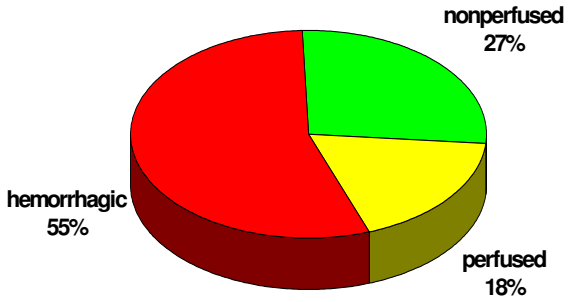

Figure 11. Distribution of patients with postoperative visual improvement ≥3 logMAR units in group A after 1 year

5.2. Retinal perfusion

At the time of the initial evaluation, nonperfusion could not be evaluated by fluorescein angiography in some eyes because retinal capillary detail was obscured by intraretinal hemorrhage and angiography was repeated as the hemorrage cleared and the retinal capillary detail could be angiographically evaluated.

In group A, FA identified before surgery nonischemic type CRVO in 8 (28,6%) cases, ischemic in 10 (35,7%) cases and hemorrhagic also in 10 (35,7%) cases. Of these 10 hemorrhagic eyes 9 (90%) were later classified as ischemic and 1 (10%) as nonischemic. We can say that 9 (32,2%) of initial 28 eyes in group A were nonischemic and 19 (67,8%) of 28 were ischemic. On the other hand, on the initial evaluation of patients in group B nonischemic CRVO was identified in 18 (51,4%) cases, ischemic in 12 (34,3%) cases and hemorrhagic in 5 (14,3%) cases. Of these 5 hemorrhagic eyes 3 (60%) were later classified as ischemic and 2 (40%) as nonischemic. This would make a definitive initial classification in group B of 21 (60%) of 35 eyes as nonischemic and 14 (40%) as ischemic (Table 9).

Table 9. Onset perfusion of the retina and corresponding Snellen visual acuity.

	Group A	Group B
Nonischemic (VA)	**28 %** 0,13	**51 %** 0,36
Ischemic (VA)	**36 %** 0,12	**34 %** 0,11
Hemorrhagic (VA)	**36 %** 0,10	**15 %** 0,50

On the last angiography performed 12 months after therapy, in group A 19 (67,8%) eyes were angiographically perfused (nonischemic) and 9 (32,2%) were nonperfused (ischemic). In group B 16 (45,7%) eyes were perfused and 19 (54,3%) eyes were classified at some point of the follow-up as nonperfused and, if indicated, underwent an additional treatment (see chapter 5.5).

Analysing these angiographic data, as on Table 10, we see that in group A 12/19 (63,1%) eyes with a preoperative nonperfusion developed retinal

perfusion after surgery, 7/19 (36,9%) of preoperatively nonperfused eyes did not develop perfusion, 7/9 (77,7%) of preoperatively perfused eyes maintained their perfused status and 2/9 (22,3%) eyes with perfusion before RON developed ischaemia despite the surgery. On the other side, in group B, 2/14 (14,3%) of nonperfused eyes developed perfusion, 12/14 (85,7%) of nonperfused remained ischemic, 14/21 (66,6%) of perfused eyes maintained a perfused retina and 7/21 (33,4%) of initially perfused eyes did develop a retinal ischemia.

We can say than in group A, perfusion of the retina improved after surgery in 63,1% (12/19) of patients as retinal status changed from ischemic to nonischemic and it worsened in 22,3% (2/9) of patients (those in which retinal status changed from nonischemic to ischemic). During follow-up, perfusion in group B spontaneously improved in 14,3% (2/14) and it worsened in 33,4 % (7/21) of patients.

Table 10. Changes in the perfusion status of the retina

	Initial		**12 months**
Group A	n=28	9 nonisch.	7 nonisch.
			2 isch.
		19 isch.	12 nonisch.
			7 isch.
Group B	n=35	21 nonisch.	14 nonisch.
			7 isch.
		14 isch.	2 nonisch.
			12 isch.

perfusion status of the retina improved from ischemic to nonischemic

perfusion status of the retina worsened from nonischemic to ischemic

5.3. Chorioretinal anastomosis

On the first visit, before any therapy was started, we could not observe the presence of any chorioretinal anastomosis in any eye in both groups. During the one-year follow-up CRA was detected with help of FA in 16/28 (57,1%) eyes in group A and 2/35 (5,7%) in group B.

In group A, 5 (31,3%) of 16 eyes that developed CRA were preoperatively classified as nonischemic and 11/16 (68,7%) were classified as ischemic. Also in group A, taking into account the development of CRA, mean preoperative VA of eyes that postoperative developed CRA (57,1%) was 0,09 and of those which did not present CRA (42,9%) was 0,14; 12 months later the mean VA in eyes with CRA was 0,22 and 0,16 in eyes with no CRA. Translated into logMAR units, the mean improvement in lines of vision achieved one year postoperative by eyes that developed CRA was 3,33 logMAR units, whereas those eyes in which we could not detect CRA showed a mean improvement of 1,28 logMAR units (Table 11). The visual improvement in eyes with CRA was significantly better than in eyes without CRA ($p<0,05$).

Table 11. Development of postoperative chorioretinal anastomosis in group A correlated with functional outcome.

	CRA	**no CRA**
% of patients	57,1 %	42,9 %
Initial VA	0,09	0,14
VA 12 months postop.	0,22	0,16
Lines of vision gained after 12 months (logMAR units)	3,33	1,28

In addition, among all operated eyes we could observe the greater development of chorioretinal anastomosis (63%) among eyes preoperatively classified as hemorrhagic, which were the ones showing the better visual improvement (2,97 logMAR units). Fifty percent of nonischemic eyes develop CRA and their mean visual improve was of 2,50 logMAR units. And ischemic eyes presented the lowest rate of CRA development (33%) and the worst visual improvement with 1,66 logMAR units (Table 12).

Table 12. Development of chorioretinal anastomosis after RON and its correlation with visual improvement (in logMAR units)

	Visual improvement	**Formation of CRA**
Nonischemic	2,50	50%
Ischemic	1,66	33%
Hemorrhagic	2,97	63%

The pictures on this page (Fig.12) correspond to a patient who suffered an hemorrhagic CRVO on his left eye. The first angiographical picture (a) is a detail of the optic nerve before surgery. At that initial point the VA was 0,05. The following images are from the FA performed twelve months after surgery, VA having improved up to 0,5. The first image of this latest angiography (b) shows the late arterial phase where the arteries are completely filled after 15 seconds and the venes are seen as hypofluorescent vessels. On the next image (c), taken one second later it is possible to recognise the site of the neurotomy at the nasal side of the optic disk. After 17 seconds (d), during venous phase, lamina flow is clearly revealed in the veins. After 18 seconds (e) the CRA shows up as a hyperreflective filled vessel while retinal veins are not completely filled yet.

Figure 12. Details of a preoperative angiography and early phase of the postoperative angiography with the CRA presenting after 18 seconds (red).

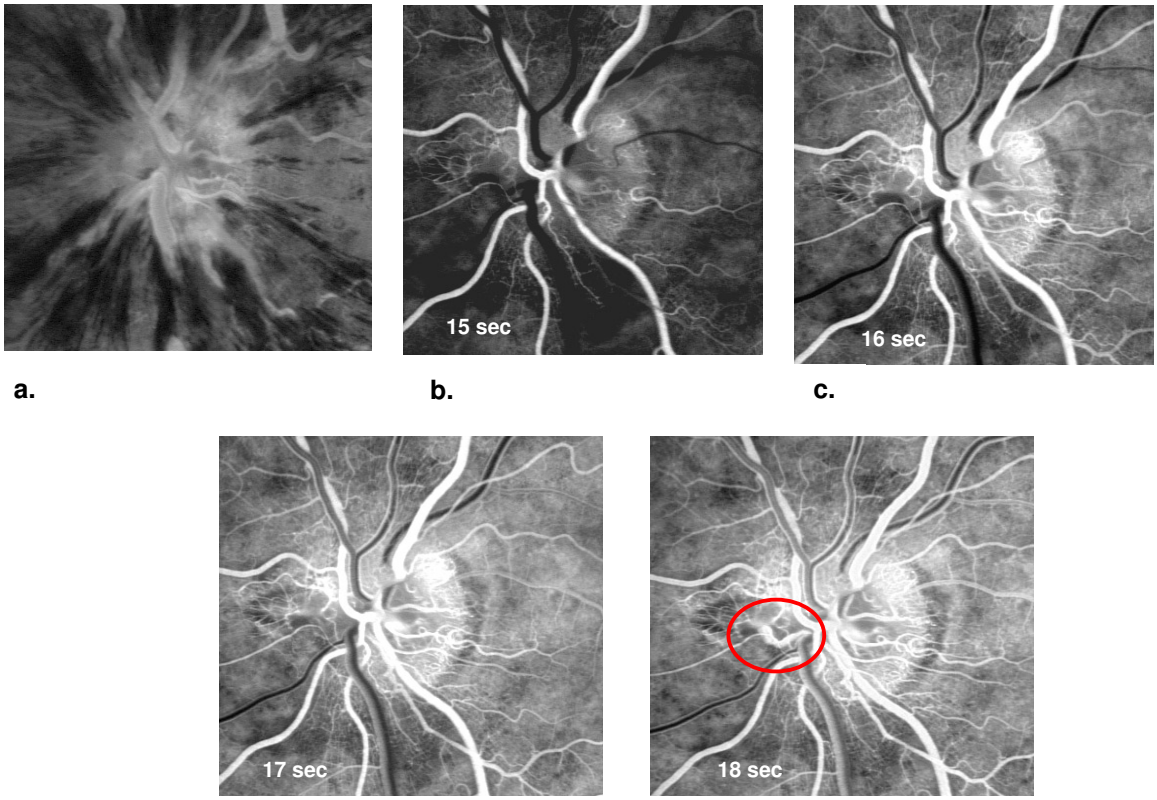

5.4. Time of arteriovenous transit

Prior to treatment, in patients of group A mean ΔT_{max} was 10,73 seconds and in group B mean ΔT_{max} was 8,33 seconds. One year later ΔT_{max} improved to 5,04 seconds in group A and 7,88 seconds in group B (Table 13). This increase in transit velocity was only statistically significant in group A ($p<0,05$).

Table 13. Time (seconds) between maximal flourescein intensity in artery and vein $T_{Vmax-Amax}$

	Group A	Group B
Initial (VA)	10,73 sec 0,1	8,33 sec 0,23
12 months (VA)	5,04 sec 0,23	7,88 sec 0,28
	$p < 0,05$	n. s.

In 16 (57%) eyes in which development of CRA at the site of the radial incision could be clinically and angiographically diagnosed, mean ΔT_{max} improved from initial 11,86 seconds to 4,16 seconds after surgery. Similarly, the mean ΔT_{max} in those 12 (43%) eyes that did not develope CRA went from 16,25 seconds to postoperative 6,46 seconds (Table 14). This similar improvement was significant within both groups ($p<0,05$) but no statistically significance could be measured between groups ($p>0,05$).

Table 14. Time between maximal flourescein intensity in artery and vein ($T_{Vmax-Amax}$) after RON, comparing development of CRA vs. no CRA

	CRA (57%)	**no CRA (43%)**
$T_{Vmax-Amax}$ initial (VA)	11,86 sec (0,10)	16,25 sec (0,24)
$T_{Vmax-Amax}$ 12 months (VA)	4,16 sec (0,23)	6,46 sec (0,28)

5.5. Complications and additional treatment

Before any therapy, by our first visit, two (7,1%) patients in group A presented iris neovascularisation, one of them with neovascular glaucoma. In group B four (11,4%) eyes had iris neovascularisation on the first control.

In group A, within the first year after surgery, 2 (7,1%) patients underwent an additional vitreoretinal surgery (one patient suffered a rhegmatogenous retinal detachment and one had a vitreous bleeding) and 3 (10,7%) patients with macular edema after surgery had to be treated with intravitreal injection of triamcinolone acetonide. During the one-year follow up we detected in group A one (3,6%) patient with high IOP, which was not among those 3 having received intravitreal triamcinolone acetonide and had no previous glaucoma, and with local therapy remained in normal values.

Even though the CVOS recommends the application of panretinal photocoagulation only when anterior segment neovascularisation develops, it also stated that the most important risk factor for predicting the occurrence of such neovascularisation is the amount of nonperfused retina. Thus, we performed postoperative panretinal photocoagulation in two (7,1%) patients in group A due to large extension of retinal nonperfusion. In group A, rubeosis

iridis developed postoperatively in one (3,6%) ischemic case. The preoperative iris neovascularisation in two patients regressed after surgery (Table 15).

In group B, during the same period of time, 2 (5,7%) patients were operated because of vitreous hemorrhage, 5 (14,3%) patients with persistent macular edema were treated with intravitreal injection of triamcinolone acetonide, one of them had afterwards an increase of IOP. Three (8,6%) eyes developed an iris neovascularisation. Eleven (31,4%) patients needed a panretinal photocoagulation therapy due to neovascularisation or ischemic signs in the retina (2 of these 10 patients received additional retinal cryocoagulation) and 4 (11,5%) patients developed an increase of IOP over normal values and had to be treated (see Table 15). Furthermore, thirteen (37,1%) patients in group B started a therapy with aspirin.

Table 15. Additional therapy during the 1-year follow-up.

	GROUP A	GROUP B
Vitrectomy	2 (7,1%)	2 (5,7%)
Intravitreous triamcinolone acetonide	3 (10,7%)	5 (14,3%)
Panretinal photocoagulation	2 (7,1%)	11 (31,4%)
Cryocoagulation	0	2 (5,7%)
Glaucoma therapy	1 (3,6%)	4 (11,5%)

6. DISCUSSION

Central retinal vein occlusion is a common retinal vascular disorder causing loss of vision in patients older than sixty years. The etiology and pathogensis are poorly understood. Pathological evidence suggests obstruction at the level or just posterior to the lamina cribosa, although histological samples of early CRVO are rare. Secondary ischemia of the retina occurs from the blood stasis in the capillary bed caused by the occluded venous system.

The Central Vein Occlusion Group reported in 1993 that vision in these patients will most likely not improve or will get worse, specially in those eyes with ischemic or hemorrhagic occlusion and initially poor vision who have, otherwise, a low chance of significant spontaneous visual recovery.

There is no widely accepted effective treatment for CRVO to date. The variability on clinical presentation and course of CRVO makes it particularly difficult to evaluate the effect of treatment options. Various treatment modalities are currently being studied, including intravitreal triamcinolone acetonide, recombinant tissue plasminogen activator given intravitreally or injected directly into a cannulated retinal vessel and anti-VEGF agents (Iturralde 2006). These procedures were not designed to relax the compressive forces at the optic nerve head and, taking CRVO as a neurovascular compression syndrome, the radial optic neurotomy was presented in 2001 by Opremcak to adress this possible pathoetiologic mechanism. Later on, it has been hypothesised that vitrectomy and posterior hyaloid peeling may help decreasing macular edema by doing the exchange between retina and vitreous cavity easier. Another recent hypothesis presents the development of chorioretinal anastomosis after RON and its following retinal blood flow improvement as the therapeutic mechanism induced by neurotomy (Garcia-Arumí 2003). Lately, RON has shown positive results in the treatment of hemicentral CRVO (Garcia-Arumí 2006).

Vogel et al (2006) have recently reported the histopathologic findings in a single human eye after RON in ischemic CRVO two weeks after onset which was enucleated 18 weeks later because of development of painful neovascular glaucoma. They found displacement of retinal tissue towards the center of the

papilla and a scar that extended into the cribiform plate attributable to RON, but could not find evidence of blood flow improvement. After performing a RON in 14 porcine eyes without retinal vein occlusion, Czajka et al (2004) observed histopathological changes including marked gliosis, complete axonal nerve fiber loss and edema at the neurotomy site.

The Central Vein Occlusion Study (CVOS 1993) studied the natural history and visual prognosis of CRVO and reported that visual acuity at baseline is a strong predictor of visual outcome at 3 years for eyes with good vision and eyes with poor vision, but a poor predictor for intermediate acuities. Thus, taking in account the importance as a predictor of preoperative visual acuity and the fact that those patients with initially poor vision have a low chance of significant spontaneous visual recovery, preoperative best corrected Snellen VA of 0,3 or worse were the criteria followed by us to indicate surgical treatment (RON) of CRVO. Furthermore, due to the reasonably good visual prognosis in patients with better levels of initial vision (VA>0,4), it did not seem prudent to us, in the absence of data to the contrary, to recommend initial treatment for eyes at this level of VA with any of the published modalities. We performed a pars plana Vitrectomy and RON in 28 patients (group A) with CRVO and 35 patients were followed as control (group B).

In the series from CVOS, a three-year follow-up including 725 patients, patients who had poor VA at the first visit (<0,1) had an 80% chance of having a VA less than 0,1 at final visit, wether perfused or nonperfused. Patients with intermediate initial VA (0,4-0,1) showed a variable outcome: 19% improved to better than 0,4, 44% stayed in the intermediate group and 37% had final VA worse than 0,1. Finally, 65% of patients with initially good VA (0,5 or better) maintained visual acuity in the same range at the end of the study. In our RON group, the results were better (Figure 13), 43% of eyes with initial VA<0,1 presented an improvement one year after surgery (versus 20% improvement expected from natural history). In eyes with initial VA 0,1 – 0,4, 50% of our operated eyes improved (versus 19% from natural history) and 7% worsened (versus 37% from natural history) . In Figure 13 the third group of the CVOS

(initial VA>0,4) is not compared since we did not perform surgery in eyes with initial VA>0,4.

Figure 13. Comparison of visual outcome after 1 year: natural history (CVOS results) vs. our RON cases.

Outcome in patients with initial VA <0,1
(worst prognosis according to CVOS)

CVOS	***RON***
80% VA <0,1	**57% VA <0,1**
19% VA 0,1 – 0,4	**36% VA 0,1 – 0,4**
1% VA ≥ 0,5	**7% VA ≥ 0,5**

Outcome in patients with initial VA 0,1 – 0,4

CVOS	***RON***
37% VA <0,1	**7% VA <0,1**
44% VA 0,1 – 0,4	**43% VA 0,1 – 0,4**
19% VA ≥ 0,5	**50% VA ≥ 0,5**

The first results of radial optic neurotomy published in 2001 by Opremcak and coworkers showed that 73% from 11 patients with poor initial VA (≤ 0,05) experienced an improvement in VA averaging 5 lines by 2 months after surgery and 45% had a final acuity of 0,25.

In posterior studies, García-Arumí (2003) presented a serie of 14 patients with a mean preoperative BCVA of 0,08 which improved to 0,25 six months after RON and with a postoperative mean of 3 lines gained. They found that 9 out of 14 eyes (64%) achieved 0,1 or better VA six months after surgery.

In the report by Nomoto et al (2004), BCVA improved in 10 (67%) of 15 eyes with a mean gain of 0,3 Snellen lines.

Weizer and coworkers (2003) described five patients with CRVO who underwent RON had a mean preoperative BCVA of 0,02, 20% were perfused and 0,05 at last postoperative follow-up.

Spaide et al (2004) reported on 6 patients with no significant visual recovery: preoperative mean VA was 0,045 and 0,05 postoperative.

Zambarakji et al (2005) reported results from RON in ten patients. 2 nonischemic, 4 ischemic. They found a trend toward visual improvement only in nonischemic eyes and a marked reduction in foveal thickness after RON.
In their latest study, including 117 cases treated with neurotomy, Opremcak et al (2006) reported a gain of 3 snellen lines in 68% of the patients. Two or more lines were gained in 53% of patients.

In our series, the 28 patients who underwent RON had a mean preoperative best corrected visual acuity of 0.10 and it increased up to 0,23 one year after surgery. We observed a visual improvement in 71,4% of our operated patients, with the greatest increase among hemorrhagic eyes (2,97 logMAR units).

The studies reporting on RON for CRVO are summarised in Table 16. There are several possible explanations for the observed differences among studies, in particular relating to case selection and assessment of vision. For instance, in the first publication from Opremcak (2001) the gain of 5 lines of vision is only among that 73% (8 of 11) of eyes that improved while in our study the 2,5 lines is the mean of all 100% operated eyes, included patients that lost vision. Other studies, like the one from Williamson only included ischemic eyes. Moreover, these are all case series, mostly retrospective with no control group and with a small sample size. It should also be taken in consideration the patient's learning ability to fixate excentrically, which may result in apparent visual improvement over time; that is why we found it necesary to compare our results with the natural history from CVOS and from our control group.

Table 16. Main studies reporting on RON for CRVO.

	no. of patients	mean preop VA	mean postop VA	Lines gained
Opremcak et al.	8	n.a.	n.a.	5
Ga.-Arumí et al.	14	0,08	0,25	3
Weizer et al.	5	0,02	0,05	0,5
Nomoto et al.	15	0,11	0,19	0,3
Spaide et al.	6	0,045	0,05	0
Marburg	28	0,10	0,23	2,5

In the serie from the Central Vein Occlusion Study Group, in the first four months of follow-up 15% of eyes with perfusion converted to ischemia. During the next 32 months of follow-up, an additional 19% of eyes were found to have converted to ischemia for a total of 34% after 3 years. The multivariate analysis of baseline characterisitcs showed that three of them were statistically significant predictors of progression to nonperfusion: duration of CRVO of less than 1 month, visual acuity of less than 0,1 and the presence of five to nine disc areas of nonperfusion based on fundus fluorescein angiography. In the study from Weizer et al (2003), perfusion status did not improve after RON. Williamson and coauthors (2003) pointed out that together with the benefitial effects upon retinal ischemia vitrectomy may have, it may also have the risk of releasing angiogenic factors into the anterior chamber causing severe neovascular glaucoma. For this reason they also performed mild panretinal photocoagulation. They were successful in reversing preoperative neovascularisation and avoiding postoperative neovascularisation. In our group A, perfusion status improved in 63,1% of initially nonperfused eyes and worsened in 22,3% of eyes. A perfusion recovery occurred in group B only in 14,3% of nonperfused eyes and, similarly to the CVOS results, 33,4% of perfused eyes became ischemic.

Development of chorioretinal anastomosis has been previously described as part of the natural history of the central retinal vein occlusion (Weinberg 1994) and they have been seen as a protection mechanism against anterior segment neovascularisation. However, we have no reliable data on how often these spontaneous anastomosis appear after an occlusion, in which time interval they appear after the occlusion or if they present a benefit for the eye. Fuller and associates (2003) described spontaneous CRA in 49 (46%) of 107 eyes with CRVO. Garcia-Arumí and co-workers (2003) reported that six (42.9%) of 14 patients in their study developed CRA between 3 weeks and 3 months after RON. In the study from Zambarakji et al (2005) CRA were observed in 60% of the operated patients. Nomoto et al (2004) described new CRA at the neurotomy site between 1 and 3 months after surgery in 7 (47%) of 15 eyes, and pointed out that, although the incidence of CRA after neurotomy was similar to that of spontaneously developed CRA, RON may cause CRA earlier than in the natural course of CRVO, leading to improvement in retinal circulation before irreversible severe retinal damage occurred. In our study, 16 (57,1%) patients developed CRA between 1 and 12 months after surgery, compared to 2 (5,7%) patients in group B. Garcia-Arumí and associates (2003) reported that five (83%) of six eyes that developed CRA were classified as nonischemic. Nomoto and associates reported that six (86%) of the seven eyes in the CRA group had nonischemic CRVO and only one (13%) of the eight eyes without CRA had nonischemic CRVO. In our series, 31,3% of eyes that developed CRA were nonischemic and 68,7% were ischemic. However these data are biased, since our group A presented a majority of ischemic eyes. In order to compensate this bias we must say that 55,5% of nonischemic eyes and 57,9% of ischemic eyes developed posoperative CRA. As a result we did not observe any difference in the development of CRA between preoperative ischemic and nonischemic eyes.

Some factors could be the cause of such difference with other reports. Firstly, many studies that report a majority of nonischemic eyes developing CRA do not take into consideration that they also have a majority of preoperative

nonischemic eyes. Maybe the retinal ischemia, if the eye is promptly operated as in our study, induces the development of the shunt vessels. However, other groups have also operated within the first weeks after occlusion and reported greater development of anastomosis among nonischemic eyes. Another possible explanation for this divergence with other results may be that among ischemic eyes the degree of nonperfusion may play a role. Thus, it may not be the same to have 10 disk areas of capillar nonperfusion or 30 disk areas of nonperfusion, and this fact has only been mentioned by Zambarakji and coauthors (2005) who doubt of any benefitial effect of RON in eyes with more than 30 disk areas of nonperfusion.

Spaide et al (2004) observed that correlation between collateral formation and VA change was positive but did not meet statistical significance, maybe because of small sample size. In a similar way, in our patients from group A the visual improvement was significantly better among eyes with formation of CRA: vision increase was 3,33 versus 1,28 logMAR units. Spaide also measured a statistically significant relationship between the caliber of the chorioretinal anastomosis and the improve of macular thickness. In our study, we have not quantified the effect of the tecnique on macular anatomy, but we have seen a lower incidence of macular edema after surgery.

Regarding retinal blood flow analysis, in the study from Nomoto and co-workers (2004), time of arteriovenous transit did not decrease after RON in most of the eyes without postoperative CRA and decreased in all eyes that developed CRA. Thus, they hypothesise that the improvement in retinal circulation after RON may be the result of postoperative CRA development. Horio et al (2006) also studied the retinal blood flow changes up to 6 months after RON in 7 eyes and could not find any significant blood flow improvement despite CRA development and significant foveal thickness reduction in all eyes. As possible explanation for resolution of macular edema without measurable blood flow improvement they mention the effect of vitrectomy alone as reported in diabetic macular edema. Shuler and Fekrat (Shuler 2006) hypothesise that major resistance to flow in CRVO is caused by microangiopathy and

microvascular resistance located in the capillary beds and that would be the reason why some studies like that from Horio (2006) show unchanged retinal blood flow measurements. Additionally, Weizer (2003) hypothesises that the removal of the posterior hyaloid may improve foveal thickness through increased oxygenation of the inner retina and thus correlate with improved visual acuity.

In our study, we found a significant decrease of the ΔT_{max} only in group A. However, ΔT_{max} in group B was initially less than in group A (12,83 sec in group A and 8,33 in group B). Additionally, the improvement was similar in eyes that had developed CRA and eyes that did not and no difference of blood flow could be measured between both groups. There may be some circumstances which help us to explain why a difference in blood flow between eyes with and without CRA development could not be measured: firstly we must point out that our method of blood flow quantification may not be accurate enough; it could also be that our method to detect CRA is not sensible enough (i.e. if any kind of bypass between retinal and choriodal circulation should take place in a deeper level we would not have been able to diagnose it by means of FA or funduscopy). It could also be that the development of CRA do not influence the blood flow as much as we suspected.

Arsène et al (2002) used a colour Doppler to evaluate the changes on arterial and venous velocities in patients with CRVO over one year. They showed a persistent impairment of central venous flow velocities in both ischemic and nonischemic CRVO, whereas velocity in the central artery was modified only in ischemic CRVO. Arteriovenous passing time improved during the follow-up only in the nonischemic group. They thought changes in arterial velocity to be a consequence of the severity of venous occlusion.

The Central Vein Occlusion Study Group (CVOS 1997) found that iris neovascularisation (INV) of at least 2-clock hours and/or angle neovascularisation (ANV) developed in 16% of eyes with CRVO. Of these eyes with neovascularisation 52% were initially categorised as nonperfused or

indeterminate and 48% as perfused. The strongest predictors of INV/ANV were VA and the amount of nonperfusion seen by fluorescein angiogram. 35% of eyes initially categorised as nonperfused or indeterminate developed INV/ANV, compared with 10% of initally perfused eyes. In the study from Weizer et al (Weizer 2003), two patients (40%) developed neovascular sequelae (choroidovitreal and iris). In our study, two patients from group A preoperatively presented rubeosis iridis that regressed after surgery. Moreover, one patient developed neovascularisation in group A after surgery. On the other hand, in group B four eyes presented iris neovascularisation by the first control and three more developed it during follow-up.

In our group A, one patient had to be reoperated due to hemorrhage in the vitreous cavity and another one suffered a postoperative retinal detachment. There have been in the literature some postoperative complications reported, such as retinal detachment (Samuel 2003) and occlusion of the central retinal artery (Yamamoto 2005), however this procedure is widely accepted as a safety technique with a low rate of complications (Meyer 2004).

7. CONCLUSIONS

1. The gain of visual acuity and also the improvement in retinal perfusion were significantly better one year after RON compared with the results of the control group.
2. We determined a significant correlation between the formation of chorioretinal anastomosis and improved visual acuity.
3. The surgical approach with vitrectomy and RON appeared to be a safe surgical technique with low incidence of complications. Furthermore, it was effective to avoid iris neovascularisation and the need for additional treatment for complications was significantly lower after surgery.

8. REFERENCES

1. Adamis AP, Shima DT, Tolentino MJ, et al. Inhibition of vascular endothelial growth factor prevents retinal ischemia-associated iris neovascularization in a nonhuman primate. Arch Ophthalmol 1996;114:66-71.
2. Aggio FA, Cariello AJ, Farah ME, et al. Bilateral central retinal vein occlusion associated with multiple myeloma. Ophthalmologica 2004;218:283-287.
3. Aiello LP, Avery RL, Arrigg PG, et al. Vascular endothelial growth factor in ocular fluid of patients with diabetic retinopathy and other retinal disorders. N Engl J Med 1994;331:1480-1487.
4. Aktan SG, Subasi M, Akbatur H. Problems of chorioretinal venous anastomosis by laser for nonischemic central retinal vein occlusion. Ophthalmologica 1998;212:389-393.
5. Appiah AP, Trempe CL. Risk factors associated with branch vs. central retinal vein occlusion. Ann Ophthalmol 1989;21:153-157.
6. Arciniegas A. Treatment of the occlusion of the central retinal vein by section of the posterior ring. Ann Ophthalmol 1984;16:1081-1086.
7. Arend O, Remky A, Jung F et al. Role of rheologic factors in patients with acute central retinal vein occlusion. Ophthalmology 1996;103:80-86.
8. Arsène S, Giraudeau B, Tranquart F, et al. Follow up by colour Doppler imaging of 102 patients with retinal vein occlusion over 1 year. Br J Ophthalmol 2002;86:1243-1247.
9. Bandello F, D'Angelo SV, Parlavecchia M, et al. Hypercoagulability and high lipoprotein(a) levels in patients with central retinal vein occlusion. Thromb Haemost 1994;72:39-43.
10. Bashshur ZF, Ma'luf RN, Noureddin B, et al. Intravitreal trimacinolone for the treatment of macular edema due to nonischemic central retinal vein occlusion. Arch Ophthalmol 2004;122:1137-1140.
11. Bhisitkul RB, Robinson GS, Moulton RS, et al. An antisense oligodeoxynucleotide against vascular endothelial growth factor in a nonhuman primate model of iris neovascularization. Arch Ophthalmol 2005;123:214-219.
12. Bloom PA, Papakostopoulos D, Gogolitsyn Y, et al. Clinical and infrared pupillometry in central retinal vein occlusion. Br J Ophthalmol 1993;77:75-80.
13. Blumenkranz MS. New therapy for central retinal vein occlusion. Are intravitreal steroids a possible answer? Arch Ophthalmol 2005;123:259-261.

14. Braendstrup P. Central retinal vein thrombosis and hemorrhagic glaucoma. Acta Ophthalmol 1950;35(suppl):1-4.
15. Brown GC, Duker JS, Lehman R, et al. Combined central retinal artery-central vein obstruction. Int Ophthalmol 1993;17:9-17.
16. Brown GC, Shah HG, Magargal LE et al. Central retinal vein obstruction and carotid artery disease. Ophthalmology 1984;91:1627-1633.
17. Bynoe L, Weiss J. Retinal endovascular surgery and intravitreal triamcinolone acetonide for central vein occlusion in young adults. Am J Ophthalmol 2003;135:382-384.
18. Cassady JV. Central retinal vein thrombosis. Am J Ophthalmol 1953;36:331-335.
19. Castella A, Othenin-Girard P. Familial occlusion of central veins associated with Type II familial hyperlipoproteinemia. Klin Monatsbl Augenheilkd 1992;200:346-348.
20. Chan C-C, Little HL. Infrequency of retinal neovascularization following central retinal vein occlusion. Trans Am Acad Ophthalmol Otolaryngol 1979;86:256-263.
21. Chew EY, Trope GE, Mitchell BJ. Diurnal intraocular pressure in young adults with central retinal vein occlusion. Ophthalmology 1987;94:1545-1549.
22. Clements DB, Elsby JM, Smith WD. Retinal vein occlusion: a comparative study of factors affecting the prognosis, including a therapeutic trial of Atromid S in this condition. Br J Ophthalmol 1968;52:111-116.
23. Coats G. Thrombosis of the central vein of the retina. R Lond Ophthalmic Hosp Rep 1906;16:62.
24. Czajka MP, Cummings TJ, Fekrat S, et al. Radial optic neurotomy in the porcine eye without retinal vein occlusion. Arch Ophthalmol 2004;122:1185-1189.
25. Dev S, Buckley EG. Optic nerve sheath decompression for progressive central retinal vein occlusion. Ophthalmic Surg Lasers 1999;30:181-184.
26. Duff IF, Falls HF, Linman JW. Anticoagulant therapy in occlusive vascular disease of the retina. Arch Ophthalmol 1951;46:601-617.
27. Duker JS, Cohen MS, Brown GC, et al. Combined branch retinal artery and central retinal vein obstruction. Retina 1990;10:105-112.
28. Elman MJ, Bhatt AK, Quinlan PM, et al. The risk for systemic vascular diseases and mortality in patients with central retinal vein occlusion. Ophthalmology 1990;97:1543-1548.
29. Evans K, Wishart PK, McGalliard JN. Neovascular complications after central retinal vein occlusion. Eye 1993;7:520-524.
30. Foster Moore R. Some observations on the intra-ocular tension in cases of thrombosis of the retinal veins. Trans Ophthalmol Soc UK 1922;42:115.

31. Fujino T, Curtin VT, Norton EWD. Experimental central retinal vein occlusion: a comparison of intraocular and extraocular occlusion. Arch Ophthalmol Soc 1969;81:395-406.
32. Fekrat S, de Juan E. Chorioretinal venous anastomosis for central retinal vein occlusion: transvitreal veni-puncture. Ophthalmolmic Surg Lasers 1999;30:52-59.
33. Fekrat S, Goldberg MF, Finkelstein D. Laser induced chorioretinal venous anastomosis for non-ischemic central or branch retinal vein occlusion. Arch Ophthalmol 1998;116:43-52.
34. Fuller JJ, Mason JO III, White MF Jr, et al. Retinochoroidal collateral veins protect against anterior segment neovascularization. Arch Ophthalmol 2003;121:332-336.
35. García-Arumí J, Boixadera A, Corcóstegui B, et al. Chorioretinal anastomosis after radial optic neurotomy for central retinal vein occlusion. Arch Ophthalmol 2003;121:1385-1391.
36. García-Arumí J, Boixadera A, Martinez-Castillo V, et al. Radial optic neurotomy for management of hemicentral retinal vein occlusion. Arch Ophthalmol 2006;124:690-695.
37. Gombos GM. Retinal vascular occlusions and their treatment with low molecular weight dextran and vasodilators: report of six years' experience. Ann Ophthalmol 1978;10:579-583.
38. Gottlieb JL, Blice JP, Mestichelli B, et al. Activated protein C resistance, factor V Leiden and central retinal vein occlusion in young adults. Arch Ophthalmol 1985;116:577-579.
39. Glacet-Bernard A, Bayani N, Chretien P, et al. Antiphospholipid antibodies in retinal vascular occlusions. A prospective study of 75 patients. Arch Ophthalmol 1994;112:790-795.
40. Glacet-Bernard A, Zourdani A, Soubrane G, et al. Effect of isovolemic hemodilution in central retinal vein occlusion. Graefes Arch Clin Exp Ophthalmol 2001;239:909-914.
41. Glueck CJ, Bell H, Vadlamani L, et al. Heritable thrombophilia and hypofibrinolysis. Possible causes of retinal vein occlusion. Arch Ophthalmol 1999;117:43-49.
42. Gradle HS. The x-ray therapy of retinal-vein thrombosis. Am J Ophthalmol 1937;20:1125-1129.
43. Green WR, Chan CC, Hutchins GM, et al. Central retinal vein occlusion: a prospective hisotpathologic study of 29 eyes in 28 cases. Trans Am Ophthalmol Soc 1981;79:371-422.
44. Hansen LL, Wiek J, Wiederholt M. A randomised prospective study of treatment of nonischemic central retinal vein occlusion by isovolaemic haemodilution. Br J Ophthalmol 1989;73:895-899.

45. Hattenbach LO, Wellermann G, Steinkamp GW, et al. Visual outcome after treatment with low-dose recombinant tissue plasminogen activator or hemodilution in ischemic central retinal vein occlusion. Ophthalmologica 1999;213:360-366.
46. Hayreh SS, Rojas P, Podhajsky P, Montague P, Woolson RF. Ocular neovascularization with retinal vascular occlusion. III. Incidence of ocular neovascularization with retinal vein occlusion. Ophthalmology 1983;90:488-506.
47. Hayreh SS, Vrabec F. The structure of the head of the optic nerve in rhesus monkey. Am J Ophthalmol 1966;61:136-150.
48. Hayreh SS, Zimmerman B, Podhajsky P. Incidence of various types of retinal vein occlusion and their recurrence and demographic characteristics. Am J Ophthalmol 1994;117:429-441.
49. Hessberg RJ. X-ray treatment of thrombosis of the retinal vein and of several types of iridocyclitis. Am J Ophthalmol 1944;27:864-870.
50. Hikichi T, Konno S, Trempe CL. Role of the vitreous in central retinal vein occlusion. Retina 1995;15:29-33.
51. Holmin N, Ploman KG. Thrombosis of central vein of retina treated with heparin. Lancet 1938;1:664.
52. Horio N, Horiguchi M. Retinal blood flow and macular edema after radial optic neurotomy for central retinal vein occlusion. Am J Opthalmol 2006;141:31-34.
53. Ip MS, Gottlieb JL, Puliafito CA, et al. Intravitreal trimacinolone for the treatment of macular edema associated with central retinal vein occlusion. Arch Ophthalmol 2004;122:1131-1136.
54. Iturralde D, Spaide RF, Meyerle CB, et al. Intravitreal bevacizumab (Avastin) treatment of macular edema in central retinal vein occlusion. A short-term study. Retina 2006;26:279-284.
55. Jaissle GB, Ziemssen F, Petermeier K, et al. Bevacizumab zur Therapie des sekundären Makulaödems nach venösen Gefäßverschlüssen. Ophthalmologe 2006;103:471-475.
56. Jonas JB, Kreissig I, Degenring R. Intraocular pressure after intravitreal injection of trimacinolone acetonide. Br J Ophthalmol 2003;87:24-27.
57. Keyser BJ, Duker JS, Brown GC, et al. Combined central retinal vein occlusion and cilioretinal artery occlusion associated with prolonged retinal arterial filling. Am J Ophthalmol 1994;117:308-313.
58. Khamashta MA, Cuadrado MJ, Mujic F et al: The management of thrombosis in the antiphospholipid-antibody syndrome. New Engl J Med 1995;332:993-997.
59. Klein BA. Occlusion of the central retinal vein: clinical importance of certain histopathologic observations. Am J Ophthalmol 1953;36:316-324.

60. Klein BA. Prevention of retinal venous occlusion. With special reference to ambulatory dicumarol therapy. Am J Ophthalmol 1950;33:175-184.
61. Klein R, Klein BE, Moss SE, et al. The epidemiology of retinal vein occlusion: the Beaver Dam Eye Study. Trans Am Ophthalmol 2000;98:133-143.
62. Kohner EM, Pettit JE, Hamilton AM, et al. Streptokinase in central retinal vein occlusion: a controlled clinical trial. Br Med J 1976;1:550-553.
63. Kornzweig AL, Eliasoph I, Feldstein M. Occlusive disease of retinal vasculature. A clinicopathological study. Arch Ophthalmol 1964;71:542-551.
64. Laatikainen L. A prospective follow-up study of panretinal photocoagulation in preventing neovascular glaucoma following ischaemic central retinal vein occlusion. Graefes Arch Clin Exp Ophthalmol 1983;220:236.
65. Laatikainen L, Kohner EM. Fluorescein angiography and its prognostic significance in central retinal vein occlusion. Br J Ophthalmol 1976;60:411-418.
66. Lam HD, Blumenkranz MS. Treatment of central retinal vein occlusion by vitrectomy with lysis of vitreopapillary and epipapillary adhesions, subretinal peripapillary tissue plasminogen activator injection, and photocoagulation. Am J Ophthalmol 2002;134:609-611.
67. Larsson J, Olafsdottir E, Bauer B. Activated protein C resistance in young adults with central retinal vein occlusion. Br J Ophthalmol 1996;80:200-202.
68. Leber T. Graefe-Seamisch Handbuch der Gestamtem Augenheilkunde. Leibzig: Englelmann, 1877;551.
69. Liebreich R. Apoplexia retinae. Albrecht von Graefes Arch Ophthalmol, 1855;1:346-351.
70. Loewenstein A, Winder A, Goldstein M, et al. Bilateral retinal vein occlusion associated with 5,10-methylenetetrahydrofolate reductase mutation. Am J Ophthalmol 1997;124:257-260.
71. Luntz MH, Schenker HI. Retinal vascular accidents in glaucoma and ocular hypertension. Surv Ophthalmol 1980;25:163-167.
72. Lureau MA, Glacet-Bernard A, Coscas G. Bilateral central retinal vein occlusion and lupus anticoagulant antibody. J Fr Ophtalmol 1995;18:468-472.
73. Magargal LE, Brown GC, Augsburger JJ, et al. Efficacy of panretinal photocoagulation in preventing neovascular glaucoma following ischemic central retinal vein obstruction. Ophthalmology 1982;89:780.
74. Magargal LE, Brown GC, Augsburger JJ, et al. Neovascular glaucoma following central retinal vein obstruction. Ophthalmology 1981;88:1095-1101.
75. McAllister IL, Constable IJ. Laser-induced chorioretinal anastomosis for treatment of central retinal vein occlusion. Arch Ophthalmol 1995;113:456.

76. Mennel S, Droutsas K, Meyer CH, et al. Radial optic neurotomy in combined cilioretinal artery and central retinal vein occlusion. Br J Ophthalmol. 2005;89:642-643.
77. Meyer CH, Gähler R. Central retinal vein occlusion in a patient with rheumatoid arthritis taking rofecoxib. Lancet 2002;360:1100.
78. Meyer CH, Mennel S, Kunze S, et al. Radiäre Optiko-Neurotomie (RON) bei Zentralvenenthrombosen. Spektrum Augenheilkd 2004;18:55-60.130.
79. Michel J. Die spontane Thrombose der Vena centralis des Opticus. Arch Ophthalmol 1878;24:37
80. Mieler WF, Blumenkranz MS. Long-term vein occlusion: risk factors, status of the fellow eye. Invest Ophthalmol Vis Sci 1982;22(suppl):69-75.
81. Mirshahi A, Roohipoor R, Mansouri MR, et al. Surgical induction of chorioretinal venous anastomosis in ischaemic central retinal vein occlusion: a non-randomised controlled clinical trial. Br J Ophthalmol 2005;89:64-69.
82. Mitchell P, Smith W, Chang A. Prevalence and associations of retinal vein occlusion in Australia. Arch Ophthalmol 1996;114:1243-1247.
83. Moshfeghi DM, Kaiser PK, Scott IU, et al. Acute endophthalmitis following intravitreal triamcinolone acetonide injection. Am J Ophthalmol 2003;136:791-796.
84. Mruthyunjaya P, Wirostko WJ, Chandrashekhar R, et al. Central retinal vein occlusion in patients treated with long-term warfarin sodium (Coumadin) for anticoagulation. Retina 2006;26:285-291.
85. Nomoto H, Shiraga F, Tsuchida Y, et al. Evaluation of radial optic neurotomy for central retinal vein occlusion by indocianine green videoangiograpjy and image analysis. Am J Ophthalmol 2004;138:612-619.
86. Opremcak EM, Bruce RA, Lomeo MD, et al. Radial optic neurotomy for central retinal vein occlusion. A retrospective pilot study of 11 consecutive cases. Retina 2001;21:408-415.
87. Opremcak EM, Rehmar AJ, Ridenour CD, et al. Radial optic neurotomy for central retinal vein occlusion: 117 consecutive cases. Retina 2006;26:297-305.
88. Osborne NN, Casson RJ, Melena J, et al. Retinal ischemia: mechanisms of damage and potential therapeutic strategies. Progress in Retinal and Eye Research 2004;23:91-147.
89. The Central Vein Occlusion Study Group. A randomized clinical trial of early panretinal photocoagulation for ischemic central vein occlusion: the Central Vein Occlusion Study Group N report. Ophthalmology 1995;102:1434-1444.
90. Pe'er J, Folberg R, Itin, et al. Vascular endothelial growth factor upregulation in human central retinal vein occlusion. Ophthalmology 1998;105:412-416.

91. Pe'er J, Shweiki D, Itin A, et al. Hypoxia-induced expression of vascular endothelial growth factor by retinal cells is a common factor in neovascularizing ocular diseases. Lab Invest 1995;72:638-645.
92. Pollack A, Dottan S, Oliver M. The fellow eye in retinal vein occlusive disease. Ophthalmology 1989;96:842-845.
93. Prisco D, Marcucci R. Retinal vein thrombosis: risk factors, pathogenesis and therapeutic approach. Pathophysiol Haemost Thromb 2002;32:308-311.
94. Quiroz-Mercado H, Sanchez Buenfil E, Guerrero-Naranjo JL, et al. Successful erbium: YAG laser-induced chorioretinal venous anastomosis for the management of ischemic central retinal vein occlusion. A report of two cases. Graefes Arch Clin Exp Ophthalmol 2001;239:872-875.
95. Remky A, Wolf S, Knabben H, et al. Perifoveal capillary network in patients with acute central retinal vein occlusion. Ophthalmology 1997;104:33-37.
96. Samuel MA, Desai UR, Gandolfo CB. Peripapillary retinal detachment after radial optic neurotomy for central retinal vein occlusion. Retina 2003;23:580-583.
97. Schmidt JC, Meyer CH, Rodrigues EB, et al. Staining of internal limiting membrane in vitreomacular surgery: A simplified technique. Retina 2003;23:263-264.
98. Schwab PJ, Okun E, Fahey FJ. Reversal of retinopathy in Waldenström's macroglobulinemia by plasmapheresis: a report of two cases. Arch Ophthalmol 1960;64:67.
99. Servais G, Thompson HS, Hayreh SS. Relative afferent pupillary defect in central retinal vein occlusion. Ophthalmology 1986;93:301-303.
100. Shuler RK, Fekrat S. Does radial optic neurotomy alter retinal blood flow in eyes with a central retinal vein occlusion? Am J Ophthalmol 2006;141:145-146.
101. Smithen LM, Ober MD, Maranan L, Spaide RF. Intravitreal triamcinolone acetonide and intraocular pressure. Am J Opthalmol 2004;138:740-743.
102. Spaide RF, Klacnik JM, Gross NE. Retinal choroidal collateral circulation after radial optic neurotomy correlated with the lessening of macular edema. Retina 2004;24:356-359.
103. Speicher L, Philipp W, Kunz FJ. Factor XII deficiency and central retinal vein occlusion. Lancet 1992;340:237.
104. Stefansson E, Novack RL, Hatchell DL. Vitrectomy prevents retinal hypoxia in branch retinal occlusion. Invest Ophthalmol Vis Sci 1990;31:284-289.
105. Stoll W, Busse H, Kroll P. Decompression of the orbit and the optic nerve in different diseases. J Craniomaxillofac Surg 1988;16:308-311.
106. Takahashi K, Muraoka K, Kishi S, Shimizu K. Formation of retinochoroidal collaterals in central retinal vein occlusion. Am J Ophthalmol 1998;126:91-99.

107. Tang WM, Han DP. A study of surgical approaches to retinal vascular occlusions. Arch Ophthalmol 2000;18:138-143.
108. The Central Vein Occlusion Study Group. Baseline and early natural history report: the Central Vein Occlusion Study. Arch Ophthalmol 1993;111:1087-1095.
109. The Central Vein Occlusion Study Group. Evaluation of grid photocoagulation for macular edema in central vein occlusion: the Central Vein Occlusion Study Group M report. Ophthalmology 1995;102:1425-1433.
110. The Central Vein Occlusion Study Group. Natural history and clinical management of central retinal vein occlusion. Arch Ophthalmol 1997;115:486-491.
111. The Eye Disease Case-Control Study Group: Risk factors for central retinal vein occlusion. Arch Ophthalmol 1996;114:545-554.
112. Vannas S, Raitta C. Anticoagulation treatment of retinal venous occlusion. Am J Ophthalmol 1966;62:874-881.
113. Vasco-Posada J. Modification of the circulation in the posterior pole of the eye. Ann Ophthalmol 1972;4:48-59.
114. Verhoeff FH. Obstruction of the central retinal vein. Ophthalmic Rev 1906;25:353.
115. Vogel A, Holz FG, Loeffler KU. Histopathologic findings after radial optic neurotomy in central retinal vein occlusion. Am J Ophthalmol 2006;141:203-205.
116. Weinberg DV, Seddon JM. Venous occlusive diseases of the retina. In Albert DM, Jakobiec FA (eds): Principles and Practice of Ophthalmology, Vol 2, p 735. Philadelphia, WB Saunders, 1994.
117. Weiss JN, Bynoe LA. Injection of tissue plasminogen activator into a branch retinal vein in eyes with central retinal vein occlusion. Ophthalmology 2001;108:2249-2257.
118. Weizer JS, Stinnett SS, Fekrat S. Radial optic neurotomy as treatment for central retinal vein occlusion. Am J Ophthalmol 2003;136:814-819.
119. Wiechens B, Schroder JO, Potzsch B et al. Primary antiphospholipid antibody syndrome and retinal occlusive vasculopathy. Am J Ophthalmol 1997;123:848-850.
120. Williamson TH. Central retinal vein occlusion: what´s the story? Br J Ophthalmol 1997;81:698-704.
121. Williamson TH, Baxter GM. Central retinal vein occlusion, an investigation by color Doppler imaging: blood velocity characteristics and prediction of iris neovascularization. Ophthalmology 1994;101:1362-1372.
122. Williamson TH, Harris JA. Ocular blood flow measurement. Br J Ophthalmol 1994;78:939-945.
123. Williamson TH, Poon W, Whitefield L, Strothoudis N, Jaycock P. A pilot study of pars plana vitrectomy, intraocular gas, and radial neurotomy in ischaemic central retinal vein occlusion. Br J Ophthalmol 2003;87:1126-1129.

124. Wolf S, Arend O, Reim M, et al. Hemodilution therapy in central retinal vein occlusion: One-year results of a prospective randomized study. Graefes Arch Clin Exp Ophthalmol 1994;232:33-39.
125. Yamamoto S, Takatsuna Y, Sato E, Mizunoya S. Central retinal artery occlusion after radial optic neurotomy in a patient with central retinal vein occlusion. Am J Ophthalmol 2005;139:206-207.
126. Zambarakji HJ, Ghazi-Nouri S, Schadt M, et al. Vitrectomy and radial optic neurotomy for central retinal vein occlusion: effects on visual acuity and macular anatomy. Graefes Arch Clin Exp Ophthalmol 2005;243:397-405.
127. Zhang CF, Hu Z. Retinal vein occlusion treatment with western medicine and traditional chinese medicine. Chin Med J 1983;96:723-730.
128. Zygulaska-Mach H, Kosta-Trabka E, Niton A, et al. Prostacyclin in central retinal vein occlusion. Lancet 1980;2:1075.

Danksagung

Mein Dank gilt Herrn Prof. Dr. Kroll für die Bereitstellung des Themas und die Möglichkeit, von seiner herausragenden Erfahrung und seinen Kenntnissen, besonders in der Retinologie, zu profitieren.
Ganz besonders möchte ich PD Dr. Meyer für seine hervorragende Betreuung danken. Seine konstruktive Kritik, seine Anregungen und seine kontinuierliche Bereitschaft, die erzielten Ergebnisse zu diskutieren und neue Ideen zu entwickeln, ermöglichte mir das Verfassen der vorliegenden Arbeit.
Des weiteren möchte ich mich für die Unterstützung bei PD Dr. Schmidt und PD Dr. Mennel bedanken.
Allen Kollegen in der Augenklinik Marburg danke ich für ihre gute Zusammenarbeit.
Ebenso möchte ich mich bei Dr. Corcóstegui und Dr. García-Arumí aus Barcelona bedanken, für Ihre Empfehlung, die Marburger Augenklinik als Ausbildungsort zu wählen. Durch sie und Prof. Kroll wurde mein Interesse an der Retinologie geweckt.
Meinen Eltern und Daniela bin ich dankbar für die Geduld und Unterstützung jeglicher Art.